

## **Therapeutic Effects of *Viscum album* Combined with *Zingiber officinale* against CCL<sub>4</sub> Induced Liver Injury in Albino Rats**

**Roseline Emeji<sup>1\*</sup>, Ndokiari Biosa<sup>2</sup> and Tamuno-Emine Davies Gabriel<sup>3</sup>**

<sup>1</sup>*School of Medical Laboratory Science, Rivers State College of Health Science and Management Technology, Nigeria.*

<sup>2</sup>*Department of Chemistry, Rivers State University, Nigeria.*

<sup>3</sup>*Medical Laboratory Science, Rivers State University, Nigeria.*

### **Authors' contributions**

*This work was carried out in collaboration among all authors. All authors read and approved the final manuscript.*

### **Article Information**

#### Editor(s):

(1) Viduranga Y. Waisundara, Rajarata University of Sri Lanka, Sri Lanka.

#### Reviewers:

(1) Nosarieme Omoregie Abey, University of Lagos, Nigeria.

(2) Eguaoje Abiodun Stanley, Univeristy of Benin, Nigeria.

Complete Peer review History: <http://www.sdiarticle3.com/review-history/50638>

**Original Research Article**

**Received 10 June 2019**  
**Accepted 20 August 2019**  
**Published 07 September 2019**

### **ABSTRACT**

This study was aimed at evaluating the efficacy of *Viscum album* (mistletoe) and *Zingiber officinale* (ginger) in treating Rat liver against CCL<sub>4</sub>-induced liver injury. Mistletoe and ginger are used in traditional medicine for the treatment of various disorders, including hepatic disorders. Biochemical parameters and histological structure were assessed and used as a measure of the therapeutic potential of the herbs against CCL<sub>4</sub>-induced liver injury. The experimental animals (15 male wistar Albino Rats) weighing between 100-120 g were randomly divided into nine (3) groups. Each group comprised 5 rats and was labelled as group 1, 2 or 3. Group 1 (negative control) animals were administered saline orally daily for 6 weeks (1ml volume per kg body weight) while group 2 (CCL<sub>4</sub> group) animals were administered CCL<sub>4</sub> mixed with olive oil as the vehicle in 1:1 ratio (3 ml/kg body weight). Group 3 represented the treatment group with extracts of the two herbal plants (250mg/kg daily). The combined herbal extracts administered orally for 6 weeks showed a significant decrease (P<0.05) in the concentrations or activities of liver function parameters including serum ALT, ALP, AST and GGT activities and serum protein, albumin, and bilirubin concentrations as compared with

\*Corresponding author: E-mail: [roselineemeji2@yahoo.com](mailto:roselineemeji2@yahoo.com);

the marked increases in the parameters in CCL<sub>4</sub>-only treated rats. Histological examination of the liver of CCL<sub>4</sub>-treated rats with the combined herbal extracts showed less destruction of liver architecture in comparison to the group treated with CCL<sub>4</sub> only. The results indicated that the combined herbal extracts investigated (mistletoe, and ginger) had a therapeutic effect against CCL<sub>4</sub>-induced liver injury and this effect could be due to the phytochemicals present in the herbs.

**Keywords:** Mistletoe; ginger; liver; albino rat; Carbon Tetrachloride (CCL<sub>4</sub>).

## 1. INTRODUCTION

The liver is one of the major vital organs for the overall physiological functions of the body. It is often regarded as a “silent organ” because it lacks inner nerve endings, it can tolerate physiological attacks and still function even at 30% of its full capacity [1]. Hepatotoxic agents can react with the basic cellular components and consequently induce almost all types of liver lesions. Toxins and drugs are among the basic etiopathogenetic agents of acute liver failure [2]. Carbon tetrachloride (CCL<sub>4</sub>) is an occupational chemical agent widely used as a solvent in insecticide. The hepatotoxicity of halogenated hydrocarbons, particularly CCL<sub>4</sub>, has been the subject of numerous investigations in experimental animals” [3]. In ages past, nature has been a relevant source of medicinal agents and an impressive number of modern drugs have been isolated from natural sources, many based on their use in traditional medicine. A number of studies have shown that plant extracts having antioxidant activity protect against CCL<sub>4</sub> hepatotoxicity by inhibiting lipid peroxidation and enhancing antioxidant enzyme activity. Studies have shown that regular consumption of fruits, vegetables and seeds can help prevent the risk of many diseases due to their content of bioactive compounds [4]. The scientific evidence regarding mistletoe’s use promising. Ginger, (*Zingiber officinale* Roscoe, Zingiberaceae) is one of the important medicinal plants that naturally occur in various countries like India, China, South East Asia, West Indies, Mexico and other parts of the world. Ginger plants are generally 1-3 ft. in height and having different chemical constituents like Amaldehyde, Gingerol, Shogaol, and Paradol etc.

Ginger has some tremendous beneficial effect on the human body to cure various types of diseases. Ginger bears an enormous number of pharmacological activities such as Neuro-protective activity and activity against colon cancer have facilitated the extent of further research for finding out less toxic and more potent drugs for the better treatment of those

diseases. The seeds are also used in folk medicine, many herbal formulations and have potential therapeutic benefits due largely to the activity of their flavonoids and other bioactive compounds” [5,6,7,8,9,10,11].

## 2. MATERIALS AND METHODS

### 2.1 Study Area/Population

The study was conducted at the Department of Human Physiology, University of Port Harcourt. It was a biological trial with Albino Wistar rats which were considered the choicest animals for this experiment because of their availability, cost, genetic makeup, handling technique and nature of the study. Fifteen (15) healthy matured male albino Wistar rats of 12weeks old weighing between 100-120 g were used in this study. The rats were obtained from the Experimental Animal Unit of the University. The rats were housed in conventional wire mesh cages under standard laboratory conditions and were allowed free access to water and feed throughout the period of the experiment.

### 2.2 Consent and Ethical Consent

Formal approval was obtained from the Department of the Biochemistry University of Port Harcourt for the biochemical analysis of the specimen for toxicity studies.

### 2.3 Preparation of Ethanolic Extract of *Garcinia kola*

Two kilograms (2 kg) of the powdery form of the *ginger* was processed at the Department of Pharmacognosy Laboratory of University of Port Harcourt for extraction using the Soxhlet extraction method. During the extraction, 70% of ethanol and 30% of water were used for the maceration. Two kilograms (2 kg) of the seeds was macerated with ethanol and water then allowed to stand at room temperature for a period of 3 days with frequent stirring until the soluble matter dissolved. The mixture then was

sieved, the damp solid material was pressed, and the solvent was clarified by filtration. The solvent was then placed in the reservoir of soxhlet for extraction. The liquid extract in the reservoir was subjected to heat for several minutes in order to vaporize the moisture. The sample was evaporated over the water bath at a temperature of 45°C and was constantly monitored until a gelatinous extract was formed.

#### 2.4 Preparation of Aqueous Leaf Extract of Mistletoe (*Viscous album*)

Two kilograms (2 kg) of the powdery form of the Mistletoe leaves was taken to the Department of Pharmacognosy laboratory of the University of Port Harcourt for extraction. During the extraction, water was used for the maceration. Two kilograms (2 kg) of the leaf was macerated with water then allowed to stand at room temperature for a period of 3 days with frequent stirring until the soluble matter dissolved. The mixture then was sieved, the damp solid material was pressed, and the solvent was clarified by filtration. The extract was then placed in the reservoir of soxhlet for extraction. The liquid extract in the reservoir was subjected to heat for several minutes in order to vaporize the moisture. The sample was evaporated over the water bath at a temperature of 45°C and was constantly monitored until a gelatinous extract was formed.

#### 2.5 Grouping and Treatment of Animals

Fifteen (15) male Albino Wistar Rats were used for this research and were divided according to their body weight into 3 groups with each group containing five (5) Rats.

- Group 1:** This was the negative control group; they received 1ml of distilled water daily for six (6) weeks.
- Group 2:** This group was induced with Carbon tetrachloride (CCL<sub>4</sub>) causing hepatotoxicity using 3 ml/kg body weight and served as a positive control.
- Group 3:** 24 hours after inducing with CCL<sub>4</sub> this group received 250 mg/kg body weight each of both Mistletoe and *Garcinia kola* and daily for six (6) weeks.

In the studied animals, hepatic injury in all groups except standard control was induced by single oral administration of CCL<sub>4</sub> mixed with olive oil as

the vehicle in 1:1 ratio (3 ml/kg of rat body weight). A pilot study was first carried out using 10 Albino Wistar Rats for each of the three (3) herbs extracts used (Mistletoe, Bitter Kola). The results obtained showed that the lethal dose was estimated at 1,500 mg/kg.

#### 2.6 Procedures for Administration of Extracts

Administration of extract was by oral gavage route. The rat was held at the skin over the head and turned so that the mouth was faced upward and the body lowered towards the holder. The syringe needle knob was then placed into the mouth of the rat a bit laterally to avoid the teeth which are centrally located. The syringe content was then gradually emptied drop by drop into the mouth of the rat.

#### 2.7 Sample Collection

The blood samples were collected from the animal via cardiac puncture and sacrificed under 70% chloroform anaesthesia into the plain specimen bottle. The samples were allowed to clot, then centrifuged at 3000 revolutions per minute for 3 minutes. Then sera obtained were stored in a freezer until required for use for analysis for liver function.

#### 2.8 Histological Studies

After 24 hours of induction and after 6weeks of the experiment (for both controls and treatment), an animal in each group was dissected and their livers tissues were histologically studied.

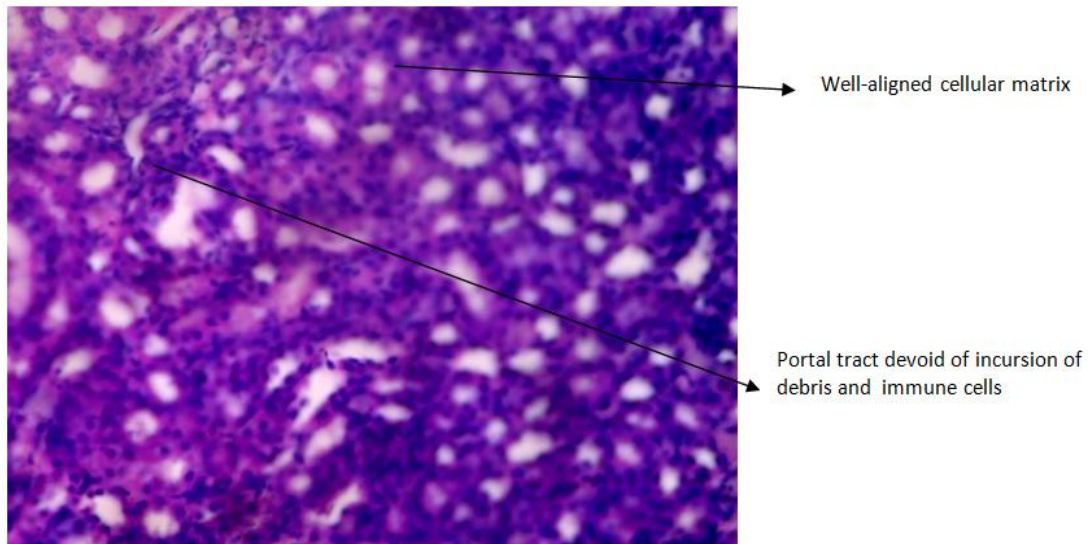
#### 2.9 Statistical Analysis

The data were evaluated statistically by SPSS version 20. Using one-way analysis of variance (one way ANOVA) and subjected to Fischer LSD post Hoc. Results were expressed as mean ±SD. Difference between means was considered significant at P<0.05.

### 3. RESULTS

#### Comparison of Parameters for Rats Treated with Combination Extracts of Mistletoe and Ginger (Group 3) with Negative and Positive Controls:

The Table 1 showed ANOVA results and Post hoc results. ANOVA results showed a significant difference in the means of the three groups (Group 1, Group 2 and Group 3) while Post hoc result showed a significant difference between in the means of the groups being compared except between Group 1 and Group 3 for AST.

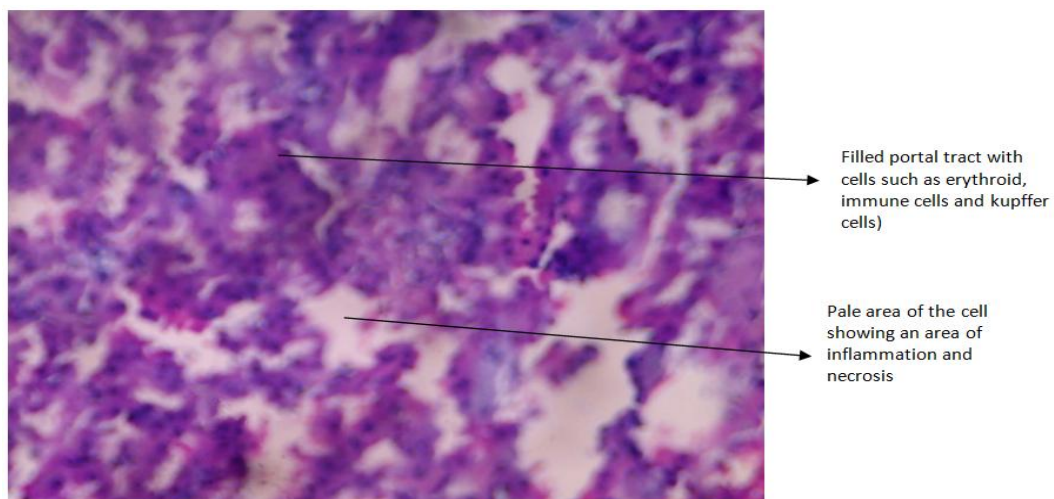


**Fig. 1. Photo micrographic slide of the liver organ of group 1 (Negative control saline) H & E X400**

#### 4. DISCUSSION

The therapeutic effects of the herbs under study; (*Viscum album* (Mistletoe) and *Zingiber officinale* (Ginger) aptly demonstrated the ability to lower the levels of alanine aminotransferase (ALT), aspartate aminotransferase (AST), and alkaline phosphatase (ALP) in Albino Wistar Rats earlier induced with  $CCL_4$ . ALT, AST and ALP are parameters that could be used to monitor the liver damage and to what extent. Hence, the drop in their levels is usually seen as a signal of recovery. The combination of the herb extracts was observed to show potency by

significantly reducing the levels of the liver enzymes (ALT, AST, ALP and GGT). The findings in this present study are similar to that reported by Edward [12] indicated the phytochemical components of these herbs may be seen to have an effective impact on hepatic recovery probably through mopping up the radicals of  $CCL_4$  that are causing the damage. This interaction may give the liver the opportunity to recover. This shows that the consumption of these herbal extracts by the rats may be increasing the rate of protein synthesis leading to a higher concentration of albumin and protein in the liver.

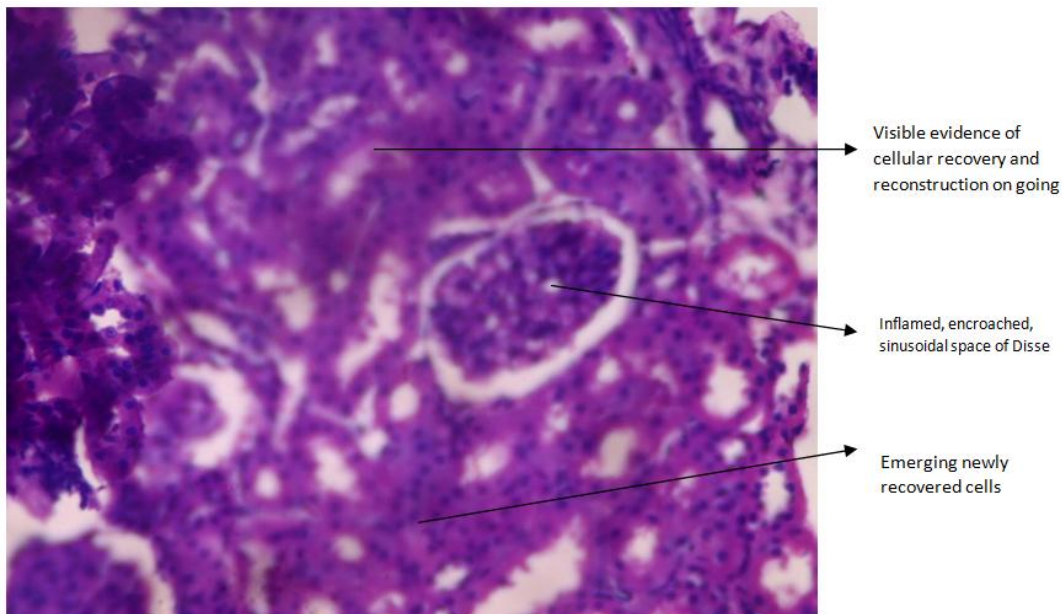


**Fig. 2. Photo micrographic slide of the liver organ of group 2 (Positive control  $CCL_4$ -induced hepatotoxicity) H & E X400**

**Table 1. Comparison of parameters for rats treated with extracts of mistletoe and ginger**

<b>Groups</b>	<b>Protein (g/L)</b>	<b>Albumin (g/L)</b>	<b>Total bilirubin (mmol/L)</b>	<b>Conj. Bilirubin (mmol/L)</b>	<b>ALT (u/l)</b>	<b>ALP (u/l)</b>	<b>GGT (u/l)</b>	<b>AST (u/L)</b>
Group 1(Negative control)	30.46± 5.44	25.96±5.01	10.41±6.09	6.78±0.64	7.60±0.89	86.0±1.00	27.98±0.78	28.40±11.50
Group 2 (positive control)	81.34±10.08	78.08±3.94	91.23±1.42	48.99±1.95	19.00±2.12	387.80±4.82	88.0±4.69	144.40±18.62
GROUP 3 mistletoe+ginger+CCL <sub>4</sub>	60.60±3.83	32.40±1.37	25.30±3.75	12.16±2.10	11.00±0.00	260.6±83.62	36.2±1.64	26.40±8.29
P-Value	<0.0001	<0.0001	<0.0001	<0.0003	<0.0001	<0.0001	<0.0001	<0.0006
F-Values	86.92	18.35	95.67	27.29	30.24	19.11	28.84	15.23
Post Hoc								
Group 1 vs Group 2	S	S	S	S	S	S	S	S
Group 1 vs Group 3	S	S	S	S	S	S	S	NS
Group 2 vs Group 3	S	S	S	S	S	S	S	S

*Values are presented in mean ±SD, n=5 per group, S=significant difference when compared*



**Fig. 3. Photo micrographic slide of the treated liver organ of group 3 using extracts of mistletoe and ginger (250 mg/kg). H & E X400**

The livers of saline control Albino Wistar Rats revealed the normal characteristic pattern of hepatic architecture (Fig. 1). The liver of Albino Wistar Rats subjected to CCL<sub>4</sub> showed disrupted or loss of liver tissue architecture, severe dilatation and congestion of blood vessels (either central veins or portal tract vessels), marked lymphocytic infiltration, and fibrosis extending between the portal areas (Fig. 2). Despite the incidence of necrosis inflicted by the CCL<sub>4</sub> treatment, there appeared significant evidence of cellular reconstruction and recovery, after treatment with the combination herbal extracts and consequently, there was a visible pattern of new cells emerging (Fig. 3).

## 5. CONCLUSION

The results of the present study suggest that mistletoe and ginger preparation may be a useful therapeutic intervention for patients with acute liver disease that have a similar mechanism of damage induced by CCL<sub>4</sub>. The mechanism(s) by which *Viscum album* and *Zingiber officinale* modulate hepatic inflammation remains, however, unclear, therefore, studies are required to elucidate the mechanism(s) by which mistletoe and ginger preparations exert their therapeutic potential as seen in the present study.

## CONSENT

It is not applicable.

## ETHICAL APPROVAL

It is not applicable.

## COMPETING INTERESTS

Authors have declared that no competing interests exist.

## REFERENCES

1. Wu M, Cheng C. Liver disease in traditional Chinese medicine. 709 Research Report of Toronto School of Traditional Chinese Medicine. 2011;1-35.
2. Ishak K, Irey N. Hepatic injury associated with the phenothiazines. Archives of Pathology. 1972;93(4):283-304.
3. Jenner AM, Timbrell JA. *In vitro* microsomal metabolism of hydrazine. Xenobiotica. 1995;25:599-609.
4. Peng W, Wu J, Wan Z, Yi J, Wu Y. Investigation of the extracts from *Bidenspilosa Linn. var. radiata* Sch. Bip for Antioxidant Activities and Cytotoxicity against Human Tumour Cells. 2013;67(1): 17-26.
5. Akintowa A, Essien AR. Protective effects of *Garicinia kola* seed extract against paracetamol-induced hepatotoxicity in rats. Journal of Ethnopharmacology. 1990;29 (2):207-211.

6. Tona L, Ngmibi NP, Tasakala M, Mesiak K, Cimanga K, Apers S Antimalarial activity of extract of 20 crude extracts from nine African medicinal plants used in Kinshasa, Congo. *Journal of Ethnopharmacology*. 1999;15(68):193-203.
7. Farombi EO. Mechanisms for the Hepato protective action of Kolaviron studies on hepatic enzymes, microtonal lipids and lipid per oxidation in carbon tetrachloride treated rats. *Pharmacological Research*. 2000;42:75-80.
8. Pietta PG. Flavonids as atioxidant. *Journal of Natural Products*. 2000;63(7):1035-1042.
9. Okunji CO, Tantalial AW, Hicks RP, Iwu MM, Skanchy DJ. Capillary electrophoresis determination of medicinal formulations. *Plant Medicine*. 2002;68:440-444.
10. Farombi EO, Okanni OO, Emerole GO. Anti oxidative and sweetening activities of Kolaviron *in vitro*. *Pharmaceutical Biology*. 2002;40:107-116.
11. Adejoke EM, Ibukun DA, Erommonselle E, Adam MA. Hepatoprotective effects of *Garcinia kola* (bitter kola) against paracetamol-induced oxidative damage and glyconge degranulation in hapatocytes of adult male Wistar rats. *Journal of Advances in Biology and Biotechnology*. 2015;3(3):110-116.
12. Edward LK. Schiff's diseases of the liver, 11<sup>th</sup> edition, New England Journal of Medicine. 2006;354(1):54-66.

© 2019 Emeji et al.; This is an Open Access article distributed under the terms of the Creative Commons Attribution License (<http://creativecommons.org/licenses/by/4.0>), which permits unrestricted use, distribution, and reproduction in any medium, provided the original work is properly cited.

*Peer-review history:*  
The peer review history for this paper can be accessed here:  
<http://www.sdiarticle3.com/review-history/50638>