



Closure of Oroantral Communications with Bichat's Buccal Fat Pad: A Case Series

Joseph Bassil¹, Ronald Younes¹, Abdallah Menhall¹ and Stephanie Mrad^{1*}

¹*Department of Oral Surgery, Faculty of Dental Medicine, Saint Joseph University of Beirut, Lebanon.*

Authors' contributions

This work was carried out in collaboration among all authors. Author JB designed the study and was chiefly involved in patients' management. Author RY also contributed in the study design and approved the final manuscript. Author AM contributed in drafting and editing the manuscript. Author SM wrote the first draft of the manuscript and managed literature searches. All authors read and approved the final manuscript.

Article Information

Editor(s):

(1) Dr. Roberta Gasparro, University of Naples Federico II, Italy.

Reviewers:

(1) Ana Valverde, Universidad Latina de Costa Rica, Costa Rica.

(2) Leonardo de Freitas Silva, Faculdade de Tecnologia e Ciências (FATEC), Brazil.

Complete Peer review History: <http://www.sdiarticle4.com/review-history/65187>

Case Study

Received 20 November 2020

Accepted 24 January 2021

Published 12 February 2021

ABSTRACT

Aims: The aim of this report is to describe the detailed surgical technique of Oroantral communication (OAC) closure with Bichat's Buccal fat pad (BFP), and to provide valuable clinical material for dental practitioners. This report also evaluates the ability of BFP to successfully seal OACs, and reports patient's satisfaction and post-operative complications.

Presentation of Cases: This case series is a retrospective study on 5 patients. Patients who presented to the medical center of Saint Joseph University of Beirut with unilateral OAC between January 2019 and July 2019 were included. Detailed surgical steps of OAC closure using the BFP are described. Data concerning patient age, perforation location and etiology, defect size, and complications are evaluated during surgery. Also, success and patient satisfaction level are registered after 3 weeks of surgery.

Results: All OACs were successfully closed with BFP and complete healing was observed 3 weeks post-operatively. Mean OAC dimensions was 8.8mm and overall patient satisfaction was 9 out of 10.

Conclusion: BFP was a simple and successful technique for OAC closure in the 5 cases. Patients were highly satisfied with the phonetic, aesthetic and functional outcomes of this surgery.

Keywords: *Oroantral communication; bichat's fat pad; buccal fat pad; maxillary sinus; case series.*

*Corresponding author: Email: stephanie.mrad1@net.usj.edu.lb, stephanie.mrad93@gmail.com;

1. INTRODUCTION

Oroantral communications (OACs) are open pathological pathways connecting oral cavity and maxillary sinus. They are mainly caused by extraction of posterior maxillary teeth that are closely related to the antral floor. OACs can also result from infectious lesions, cysts, trauma, tuberosity fracture, osteoradionecrosis, or implant placement in the maxillary sinus [1]. Large communications could cause, following saliva and food accumulation, chronic sinusitis and oroantral fistulas. Therefore, large OACs (>2mm) need to be surgically closed to avoid complications. The classical treatment options are vestibular or palatal flaps, and pedicled Bichat's buccal fat pad (BFP) [2]. The use of Bichat's fat pad for OAC's closure was first proposed by Egyedi in 1977 [3]. Later, Tiedeman et al. described, in a 12-case series, the surgical technique for oral defect reconstruction [4]. Hanazawa et al. described the progressive post-operative transformation of orally exposed fat pad into granulation tissue then into epithelial soft tissue within 3 weeks [5]. However, the exhaustive surgical technique using BFP to close OACs is rarely described in literature. BFP is anatomically delimited by the ascending mandibular branch, the zygomatic arch, and the masseter and buccinator muscles. This encapsulated adipose tissue mass is composed of a main body located along the posterior maxilla and four processes extending into temporal, pterygoid, pterygopalatine, and buccal muscles [6]. The aim of the present series is to describe the detailed surgical technique and report the benefits and risks of Bichat's buccal fat pad used to treat 5 cases of oroantral communications.

2. PRESENTATION OF CASES

2.1 Study Sample

Patients who presented to the medical center of Saint Joseph University of Beirut between January 2019 and July 2019 with unilateral OACs were screened. At presentation, these patients complained of liquid nasal regurgitation, nasal resonance alteration, and in some cases pain at the malar area. OAC diagnosis was made by an intra-oral examination and a positive Valsalva maneuver. An orthopantomogram was done to exclude the presence of sinus pathologies.

2.1.1 Inclusion criteria

Inclusion criteria were: Age >18 years; no systemic diseases; none or light smokers (≤ 10 cigarettes/day); small or medium-sized oral defects (≤ 5 cm).

2.1.2 Exclusion criteria

Exclusion criteria were: Sinus pathology; presence of oroantral pus secretion.

2.2 Surgical Technique

After local anesthesia, the surgical procedure was initiated with a linear crestal incision, and 2 vertical mesial and distal incisions. Afterwards, a circumferential incision around the OAC, 2mm larger than its borders, was effectuated to excise all inflammatory tissues (Fig. 1.a.), and a full-thickness trapezoidal flap extending from both defect sides till the buccal sulcus was raised. A 1 cm incision was made on the reflected periosteum, posterior to the zygomatic buttress, and into the buccinator muscle (Fig. 1.b.). Blunt dissection was carefully performed to separate buccinator's fibers and access Bichat's fat pad without injuring the overlying capsule. In some cases, when a sufficient opening was created, the buccal extension of Bichat's fat pad spontaneously herniated, in the other cases, it was drawn out with tissue forceps (Fig. 1.c., 1.d.). Traction of the needed pedicled volume was effectuated to ensure complete sealing of the defect (Fig. 1.e.). The repositioned buccal pad was covered as much as possible with the reflected flap and fixed with minimal tension sutures (Fig. 1.f.).

In one case (case 3), a window was created in the lateral sinus wall and pedicled pad was tracted through this window (Fig. 2.).

In case 5 a textured collagen dressing was placed before grafting the fat pad.

A post-operative soft diet was recommended to avoid any trauma to the surgical site. Also, patients were instructed to avoid nose blowing, coughing and sneezing with a closed mouth, straw usage, and smoking for the following month. Amoxicillin (1g) was prescribed twice/day for 7 days post-surgically, Ibuprofen 400mg 3 times/day when needed, in association with decongestant nose drops, and 0.12% chlorhexidine digluconate rinses 3 times/day for two weeks. Sutures were removed 1 week after surgery. Control visits were performed at 1 and 3 weeks post-surgery (Fig. 3).

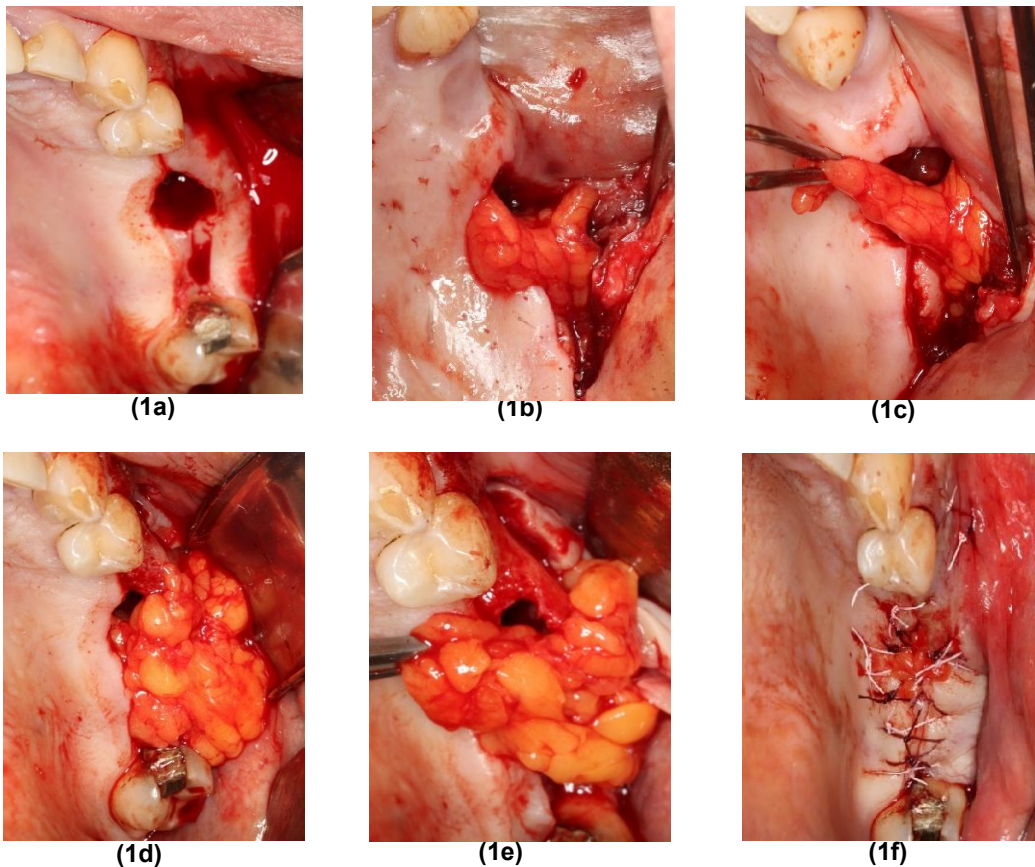


Fig. 1. Pedicled Bichat's buccal fat pad used to close OAC at the upper left first molar level. a. Linear and circumferential crestal incisions around OAC borders (case 1). b. Blunt dissection on the reflected periosteum to access BFP (case 2). c. BFP drawn out with tissue forceps (case 2). d. Buccal process of the fat pad spontaneously herniating into the oral cavity after blunt dissection of buccinator fibers (case 1). e. BFP mobilization and traction to cover the communication (case 1). f. Suturing and stabilizing the BFP to completely seal the communication (case 1)

2.3 Measured Variables

In this series, the assessed variables were: Pre-operatively: patient age, and perforation etiology and location; Per-operatively: bony defect size in its largest mesiodistal diameter (in mm using a periodontal probe "PC 15/11.5, Hu-Friedy"), surgical complications (excessive bleeding, flap tension, Etc.); Post-operatively: re-occurrence of perforation, and symptoms at 1 week. Also, a visual analog scale (VAS) from 1 to 10 was used to assess overall satisfaction of aesthetic, phonetic and chewing function.

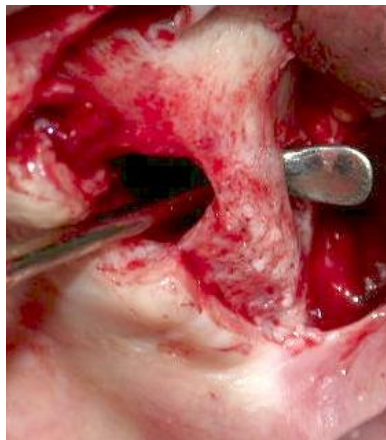2.4 Study Outcomes

A total of 5 OACs treated with pedicled BFP were included in this study. Mean patient age was 45.8

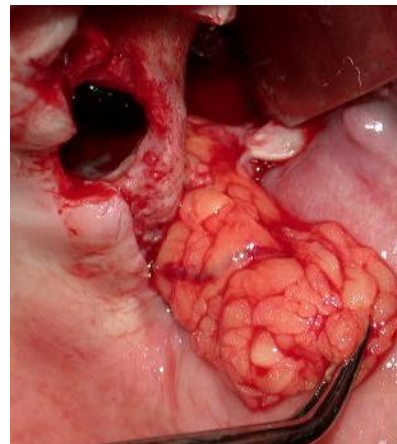
ranging between 36 and 54. In all cases, unilateral OAC was caused by simple dental extractions of an upper third molar (1 case), an upper second premolar (1 case), and upper first molars (3 cases). In one case a cystectomy was effectuated after the extraction. OAC dimensions ranged between 6 and 12mm (mean 8.8 mm). No complications occurred during any of the surgeries. Patients experienced several symptoms such as pain, edema, trismus, suppuration and halitosis, mostly in the first 3 days post-op (Table 1). OACs did not persist in any of these 5 cases. 3 weeks after surgery, complete closure and epithelialization were observed in all cases. On the visual analog scale, a mean of 9 was assessed according to aesthetic, phonetic and functional parameters.

Table 1. Study variables

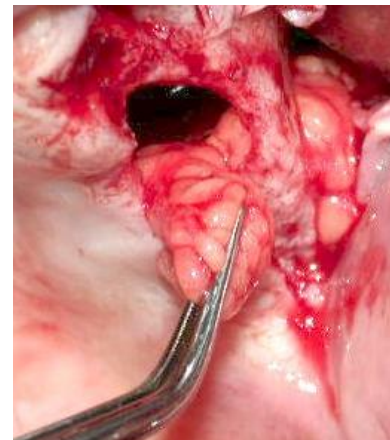Case	Age	Etiology	Location	Size (mm)	Per-operative complications	Post-operative symptoms	Re-incidence of OAC	Patient satisfaction (VAS at 3 weeks)
1	44	Extraction of 16#	1 st molar zone	6	None	Trismus and Edema	No	8.8
2	49	Extraction of 28#	Tuberosity zone	10	None	Pain, Edema and Trismus	No	8.2
3	36	Extraction of 16#	1st molar zone	8	None	Pain and Edema	No	9
4	52	Extraction of 25# + cystectomy	1st molar and 2nd premolar zone	8	None	None	No	10
5	48	Extraction of 16#	1 st molar zone	12	None	Pain, Suppuration and Halitosis	No	9



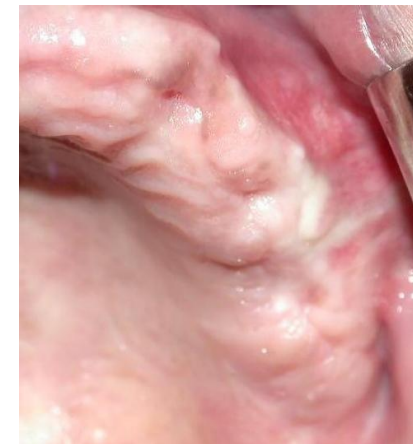(2a)



(2b)



(2c)



(2d)

Fig. 2. Description of case 3. a. Window created in the lateral sinus wall. b. BFP drawn out with tissue forceps. c. BFP tracted through the lateral wall to cover the crestal communication. d. View of the surgical site 3 weeks post-operatively

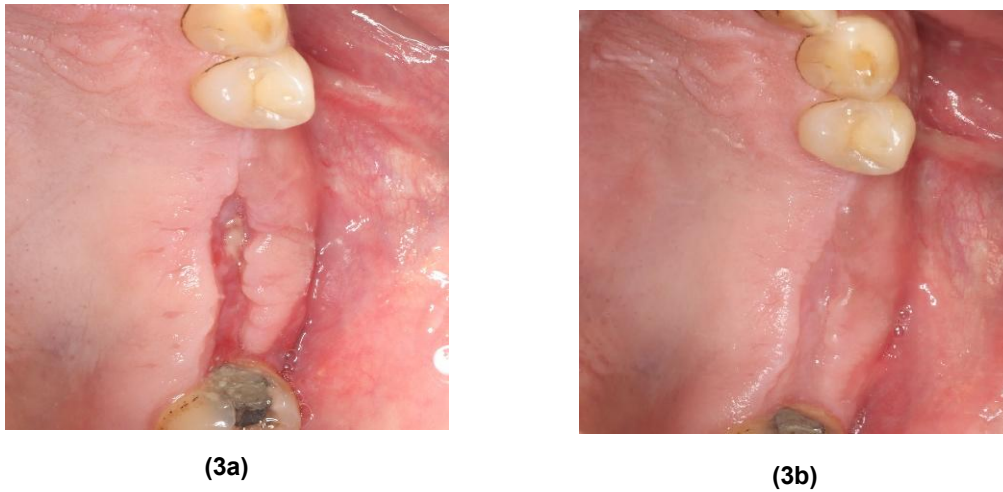


Fig. 3. Post-operative follow-up of case 1. a. View of the surgical site 1 week post-operatively. b. View of the surgical site 3 weeks post-operatively

3. DISCUSSION

This report describes 5 cases of open communications between the maxillary sinus and the oral cavity. Extraction of first molars was the most frequent OAC etiology encountered in this case series. This is in accordance with several studies where extraction of posterior upper teeth, in particular 1st molars, was the main OAC etiology. In fact, it was demonstrated that roots of maxillary premolars and molars are closely related to the sinus antrum: the bone lamella separating these teeth from the maxillary sinus floor can be as thin as 0.5 mm in many cases; also 1st molar apices perforated the sinus floor in 2.2% of the cases [7]. Nevertheless, other etiologies of OAC were described in the literature such as trauma, odontogenic pathology (periodontal or endodontic infections), infectious pathology in the sinus antrum, sinus floor elevations, implant surgery, removal of failed implants, and tumor/cyst removal, as in one of the described cases in this report [7].

Many techniques and materials have been proposed for the treatment of OAC. Among these materials, the sandwich technique combining Bio-Oss (xenograft) placed between 2 sheaths of Bio-Gide (collagen membrane), and the GBR combining autogenous and xenogeneic particles with an expanded non-resorbable membrane (e-PTFE) allowed regeneration of both soft and hard tissues for later implant placement [8]. New synthetic materials such as bioabsorbable tricalcium phosphate root analogs, biodegradable polyurethane foam and non-porous

hydroxyapatite blocks present successful treatment outcomes, but they are very expensive and their surgical manipulation needs to be simplified [9].

Autologous tissues can also be used to close perforations such as tongue flaps, extra-oral (iliac crest) and intra-oral autogenous bone (zygoma, the chin or the retromolar zone) covered by resorbable membranes, 3rd molar transplantation, platelet-rich fibrin (PRF), coverage flaps, and Bichat's buccal fat pad (BFP) [9].

BFP is an autologous adipose mass situated in the posterior maxilla, superficially within the cheek and buccinator's fibers, and is covered by a thin capsule [6]. In this case series, after raising a full-thickness flap, a simple horizontal incision is made in the periosteum facing the tuberosity area to easily gain access to the adipose tissue. BFP is also highly supplied by the maxillary, temporal (superficial and deep), and other facial arteries. Important vascularization and favorable anatomical location close to the recipient site make it possible to use this structure for OAC closure with minimal risk of necrosis and high success rate [9,10].

This technique showed an overall success rate of 96.2% in a recent literature review: re-incidence of perforations appeared only in 12 out of 319 cases [6]. In a retrospective study of 130 OACs, BFP assured effective closure in 98% of the cases [7]. Similar results were found in the present report, where OACs were successfully

treated by a pedicled BFP and consistent epithelialization of the originally uncovered BFP was clinically observed in all cases. Histological findings of Baumann et al. confirm the presence of a normal stratified squamous epithelium above the BFP [11].

At 1 month postoperatively, the mean score of patient satisfaction levels regarding aesthetic, phonetic, and functional was 9 out of 10 (range 8.2 to 10), denoting good patient satisfaction rate. In a recent study, Alonso-Gonzalez et al. found similar satisfaction levels in phonetics, aesthetics, and chewing; with an overall of 9.1 out of 10 [10]. Therefore, the use of BFP for OAC closure is considered very satisfying for patients.

A recent study illustrated the factors that need to be considered in the decision-making of OAC closure such as time of occurrence, prosthetic treatment plan, sinus status, and mainly the defect size and location. Parvini et al. stated that openings smaller than 2mm heal spontaneously in absence of sinus pathology, and defects larger than 5mm in diameter or that lasted for more than 3 weeks require surgical intervention [12]. When measured at their largest diameter, all OACs in this report ranged between 6 and 12mm and therefore required surgical intervention to be closed. If not treated, these sites could cause contamination and chronic infection of the corresponding sinus. The maximal defect size that can be covered by BFP is controversial [7]. Coverage of perforations up to 70mm have been described in literature; however, BFP is usually recommended when perforations do not exceed 50mm in size to avoid necrosis and excessive flap tension [13].

The most frequently described post-operative complications of this technique are infection, partial rupture or necrosis of the flap, and OAC persistence. Poeschi et al. described postoperative trismus and pain that lasted for several weeks [7]. In this report, none of the described cases showed severe complications or OAC re-incidence. However, some patients experienced suppuration, edema, and halitosis for a short period of time.

The BFP technique has numerous advantages: Bichat's fat pad is independent from patient general health, age or sex; surgical procedure is relatively simple and can be associated to second layer flaps if necessary; side effects are rare and temporary; donor site presents minimal

morbidity; success rates are elevated; future prosthetic treatment is possible after this surgery [12]. Also, BFP has its own lipolysis mechanism that is independent of other subcutaneous body fats and thus BFP can be successfully used in all patients [14].

The main drawback of BFP is that it can only be used once. The use of BFP is not recommended for OACs larger than 50 mm in diameter. Also, this technique is contraindicated for smokers and in case of sinus pathology. The major limitations of this study are the restricted number of included patients and the absence of a control or a comparative group.

Recently, pre-clinical researches showed that BFP contains adipose-derived stem cells that can differentiate and proliferate into osteogenic cells. Therefore, further research on the possible roles of BFP adipose-derived stem cells in hard and soft tissue engineering is required to confirm these results [15].

4. CONCLUSION

Several treatment options for oroantral communication closure were described in literature. OAC closure using Bichat's buccal fat pad is a simple and effective method: this report describes 5 cases of oroantral communications successfully treated with Bichat's buccal fat pad. BFP is highly vascularized, elastic and close to the defects; thus, it can ensure high success rates of OAC closure and normal epithelialization of the recipient site 3-weeks post-surgery. Post-operative side effects are temporary, and patients are usually highly satisfied with the phonetic, aesthetic and functional outcomes of this surgery.

CONSENT

Patient consent to participate: Informed and written consent was obtained from all individual participants included in the study for participation, for taking pictures, and for submitting this report.

ETHICAL APPROVAL

"Due to the retrospective nature of this study, it was granted an exemption by the Saint Joseph University of Beirut IRB, and have therefore been performed in accordance with the ethical standards laid down in the 1964 Declaration of Helsinki."

COMPETING INTERESTS

Authors have declared that no competing interests exist.

REFERENCES

1. Hernando J, Gallego L, Junquera L, Villarreal P. Oroantral communications. A retrospective analysis. *Med Oral Patol Oral Cir Bucal*. 2010;15(3):499–503.
2. Hirata Y, Kino K, Nagaoka S, Miyamoto R, Yoshimasu H, Amagasa T. A clinical investigation of oro-maxillary sinus-perforation due to tooth extraction. *Kokubyo Gakkai zasshi The Journal of the Stomatological Society, Japan*. 2001;68(3):249.
3. Egyedi P. Utilization of the buccal fat pad for closure of oro-antral and/or oro-nasal communications. *Journal of maxillofacial surgery*. 1977;5:241–4.
4. Tideman H, Bosanquet A, Scott J. Use of the buccal fat pad as a pedicled graft. *Journal of Oral and Maxillofacial Surgery*. 1986;44(6):435–40.
5. Ramadan N. The use of Buccal Pad of Fat Versus Leukocyte-Platelet Rich Fibrin for Closure of Oroantral Communication. *Egyptian Dental Journal*. 2020;66(2-April (Oral Surgery)):893–903.
6. Kim M-K, Han W, Kim S-G. The use of the buccal fat pad flap for oral reconstruction. *Maxillofac Plast Reconstr Surg*. 2017;39(1):5.
7. Poeschl PW, Baumann A, Russmueller G, Poeschl E, Klug C, Ewers R. Closure of oroantral communications with Bichat's buccal fat pad. *Journal of Oral and Maxillofacial Surgery*. 2009;67(7):1460–6.
8. Batra H, Jindal G, Kaur S. Evaluation of different treatment modalities for closure of oro-antral communications and formulation of a rational approach. *Journal of Maxillofacial and Oral Surgery*. 2010;9(1):13–8.
9. Khandelwal P, Hajira N. Management of oro-antral communication and fistula: Various surgical options. *World Journal of Plastic Surgery*. 2017;6(1):3.
10. Alonso-González R, Peñarrocha-Diago M, Peñarrocha-Oltra D, Aloy-Prósper A, Camacho-Alonso F, Peñarrocha-Diago M. Closure of oroantral communications with Bichat's buccal fat pad. Level of patient satisfaction. *Journal of Clinical and Experimental Dentistry*. 2015;7(1):e28.
11. Baumann A, Ewers R. Application of the buccal fat pad in oral reconstruction. *Journal of Oral and Maxillofacial Surgery*. 2000;58(4):389–92.
12. Parvini P, Obreja K, Begic A, Schwarz F, Becker J, Sader R, et al. Decision-making in closure of oroantral communication and fistula. *International Journal of Implant Dentistry*. 2019;5(1):13.
13. Singh J, Prasad K, Lalitha RM, Ranganath K. Buccal pad of fat and its applications in oral and maxillofacial surgery: A review of published literature (February) 2004 to (July) 2009. *Oral Surgery, Oral Medicine, Oral Pathology, Oral Radiology, and Endodontology*. 2010;110(6):698–705.
14. Khandelwal P, Hajira N. Management of oro-antral communication and fistula: various surgical options. *World Journal of Plastic Surgery*. 2017;6(1):3.
15. Niada S, Ferreira LM, Arrigoni E, Addis A, Campagnol M, Broccaioli E et al. Porcine adipose-derived stem cells from buccal fat pad and subcutaneous adipose tissue for future preclinical studies in oral surgery. *Stem Cell Research & Therapy*. 2013;4(6):1–11.

© 2021 Bassil et al.; This is an Open Access article distributed under the terms of the Creative Commons Attribution License (<http://creativecommons.org/licenses/by/4.0>), which permits unrestricted use, distribution, and reproduction in any medium, provided the original work is properly cited.

Peer-review history:

The peer review history for this paper can be accessed here:
<http://www.sdiarticle4.com/review-history/65187>