



Osteitis Fibrosa Cystica of Jaws as Diagnostic Criteria for Hyperparathyroidism – A Case Report with Review of Literature

**S. N. Santhosh Kumar^{1*}, Kalyani Bhate¹, Vivek Pawar¹, Kapil Kshirsagar¹,
Vijay Gupta¹, Sushmita Mitra¹ and Suraj Bangar¹**

¹Department of Oral and Maxillofacial Surgery, Dr. D.Y. Patil Vidyapeeth,
Dr. D.Y. Patil Dental College and Hospital, Pimpri, Pune 18, India.

Authors' contributions

This work was carried out in collaboration between all authors. All authors read and approved the final manuscript.

Article Information

DOI: 10.9734/IJMPCR/2016/24344

Editor(s):

(1) Manuel Marques Ferreira, Area of Dentistry, University of Coimbra, Portugal.

Reviewers:

(1) Mra Aye, Universiti Kuala Lumpur Royal College of Medicine Perak, Malaysia.

(2) Alexander Berezin, Medical University, Zaporozhye, Ukraine.

(3) Abrao Rapoport, Sao Paulo University, Brazil.

Complete Peer review History: <http://sciencedomain.org/review-history/13434>

Case Study

Received 15th January 2016
Accepted 6th February 2016
Published 25th February 2016

ABSTRACT

Maxillo-mandibular swellings are one the common presentations with which, patient approach a surgeon. These maxillo-mandibular swellings may be reactionary, benign, malignant and sometimes secondary to some underlying systemic disorders. There is a necessity for the surgeons to deviate from the traditional surgical management for those maxillo-mandibular swellings secondary to underlying systemic disorders. Here is a case report of 46-year old female who complained of swelling in the right maxilla and left mandible secondary to brown tumour, with an emphasis on the protocol for the management.

Keywords: Giant cell lesions; hyperparathyroidism; brown tumor; osteitis fibrosa cystic.

*Corresponding author: E-mail: sunnysn04@yahoo.co.in;

1. INTRODUCTION

Maxillo-mandibular swellings are one of the common presentations with which, patient approach a surgeon. These swellings may be reactionary, benign, malignant and sometimes secondary to some underlying systemic disorders. There is a necessity for the surgeons to deviate from the traditional surgical management for those maxillo-mandibular swellings secondary to underlying systemic disorders. Brown tumour is one such systemic disorder that may present as maxillo-mandibular swelling, accounting for 4.5% - 11.8% of the cases [1].

Brown tumour is one of the clinical manifestations of primary or secondary hyperparathyroidism, third most common endocrinal disease [2,3]. Hyperparathyroidism is a condition resulting from increased parathormone secretion [4]. Brown tumour, a giant cell granuloma occurring in osteitis fibrosis cystica, represents the terminal stage of the bone remodelling processes occurring as a result of peritrabecular fibrosis and osteoclastic activity [5,6]. It is a component of a metabolic bone disease recognized as osteitis fibrosa cystica generalisata or Recklinghausen's disease of bone [7]. It usually occurs in the long bones, pelvic girdle, clavicle, ribs, and the mandible. Maxilla is a rare site for Brown tumour [1].

Here is a rare case report of 46-year old female who complained of swelling in the maxillo-mandibular region secondary to brown tumour, with an emphasis on the protocol for the management of the same.

2. CASE IN DETAIL

A 46-year old female patient reported to the department of oral and maxillofacial surgery with swelling of the right back region of the upper jaw ten months back. She gave a history of peanut sized swelling on the palatal surface of the right back region of the upper jaw and has progressed to the present size over a period of three months. She did not give any previous medical history and harmful habits.

She was moderately built and nourished. She walked with high steppage gait. Blood pressure was found to be 110/78 mm of Hg. Other vital signs were within normal limit. No pallor, icterus, clubbing and cyanosis were present.

On examination, significant facial asymmetry was noted. There was diffuse swelling in the right infraorbital region. Also, a diffuse swelling was situated in the left mental foramen region.

Intraorally, there were two ovoid swellings:

1. A sessile swelling in the right maxillary posterior alveolus extending from the tuberosity to the second premolar antero-posteriorly and from the maxillary vestibule to occlusal plane supero-inferiorly, measuring around 3 X 2.5 cm, obliterating the maxillary posterior vestibule. The overlying mucosa was stretched with reddish discoloration. Indentations of teeth were present on the overlying mucosa causing ulcerations and necrosis. Palpation revealed irregular surface of the swelling. It was non-tender and firm in consistency (Fig. 1).
2. Another sessile swelling was present in the left mandibular molar region extending from first molar to second molar antero-posteriorly and from the alveolus to the vestibular depth supero-inferiorly, measuring around 1.5 X 0.5 cm. It was hard or bony consistency on palpation.

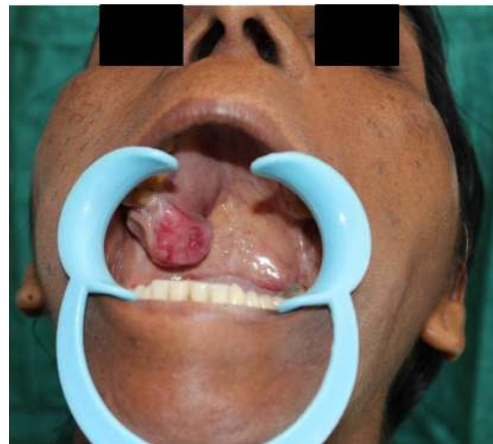

Fig. 1. Ovoid, sessile swelling in the right maxillary posterior alveolus

Upper right second molar was buccally displaced and grade II mobility in relation to 15, 16, 17. Teeth associated with the swelling were non-carious and vital.

Based on the history and clinical findings, a diagnosis of pyogenic granuloma of the posterior maxilla and primordial cyst.

Orthopantomograph (OPG) showed slightly displaced upper right third molar and well-defined periapical radiolucency in the left mandibular first and second molar region. Occipitontal view revealed clear maxillary sinuses bilaterally. An incisional biopsy was performed for the right posterior maxillary lesion under local anaesthesia and sent for histopathological examination. Histopathological examination revealed squamous epithelium with subepithelial proliferation of multinucleate giant cells having 8-12 nuclei and cellular vascular stroma composed of fibroblasts. Areas of haemorrhage were also present. The histopathologic diagnosis was reparative giant cell granuloma.

Then, following blood investigations were undertaken to rule out hyperparathyroidism-serum calcium level, serum alkaline phosphatase and paratharmone assay. Serum calcium level was normal (9 mg %). However, serum alkaline phosphatase and paratharmone levels were greatly elevated. Serum alkaline phosphatase was 1148 IU/L and serum paratharmone was 1133 pg/ml. Blood urea, creatinine, Serum albumin, coagulation profile, full blood count and full blood picture were all within normal limits. Vitamin D level and ionic calcium levels were also found to be within normal limits.

The patient was then referred to radiology department for X-ray pelvis, CT scan of head and neck and ultrasound neck and abdomen. X-ray pelvis revealed no abnormalities. CT scan of head and neck revealed several radiolucent lesions on the frontal bone, maxilla and mandible (Fig. 2).

USG neck showed a well defined round to oval predominantly hypoechoic lesion posterolateral to left lobe of thyroid displacing it anteromedially, suggestive of left parathyroid gland adenoma (Fig. 3).

USG abdomen revealed gall bladder sludge, left simple renal cortical cyst and right non-obstructive renal calculi (Fig. 4).

The final diagnosis was *Brown tumour secondary to primary hyperparathyroidism associated with gall bladder sludge, right renal calculi and left renal cortical cyst.*

The following treatment was planned – parathyroidectomy, follow-up of around 1 year and excision and curettage of the maxillo-mandibular swellings.

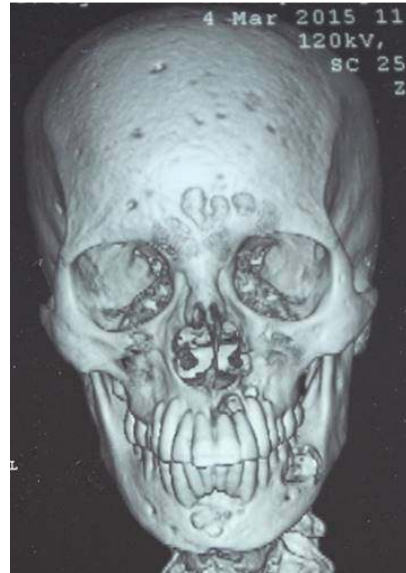

Fig 2. 3-D computed tomography showing

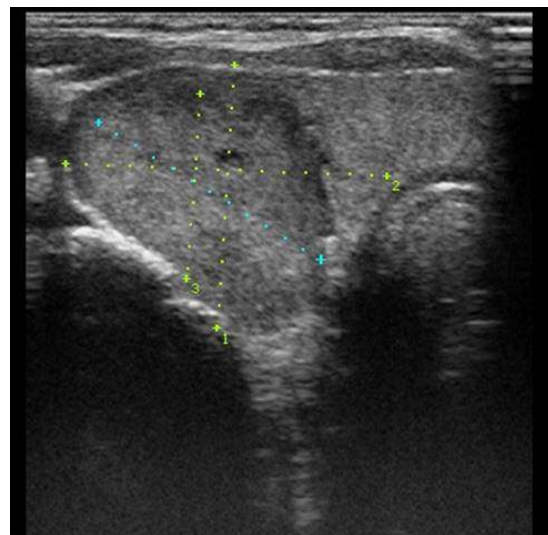


Fig. 3. USG neck showing hypoechoic lesion in left parathyroid gland, displacing left thyroid lobe

The patient was referred to the department of general surgery for parathyroidectomy. Postoperatively, calcium and multivitamin supplements were prescribed for life-time. The patient is being followed up for every 3 months. During the first follow-up at 3rd postoperative month, marked reduction in the size of the maxillary swelling was noted clinically (Fig. 5). Serum parathormone levels reduced to 235 pg/ml.

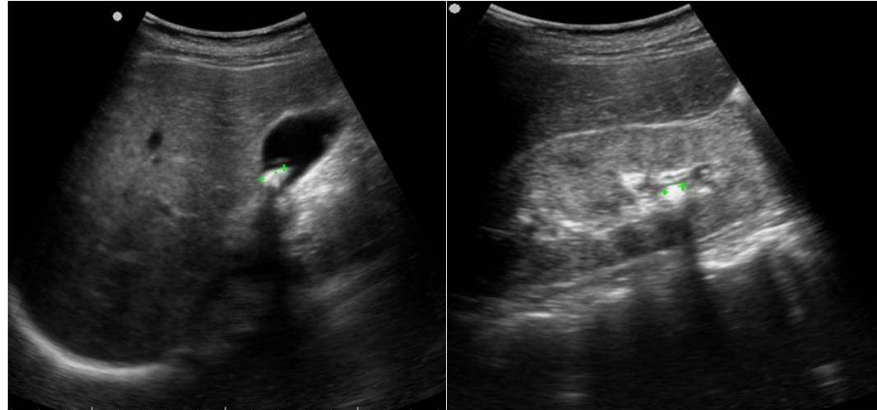


Fig. 4. USG abdomen revealing gall bladder sludge, left simple renal cortical cyst and right non-obstructive renal calculi

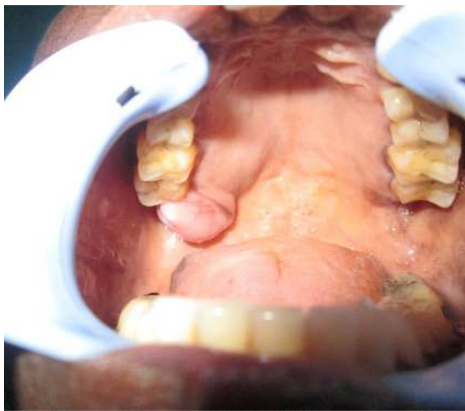

Fig. 5. Marked reduction in intraoral maxillary swelling

The reported prevalence of brown tumours is 0.1% [9]. Primary hyperparathyroidism in 80% of the cases is due to a parathyroid adenoma; in over 15% of the cases it is due to a glandular hyperplasia, and extremely rare due to a parathyroid adenocarcinoma [10].

The commonly involved sites are facial bones, clavicle, ribs, pelvis and femur. They are more common in mandible compared to maxilla. This bony lesion is caused by increased circulating levels of parathyroid hormone, which result in increased osteoclastic bone resorption, primarily in cortical bone. This may explain why the mandible, a cortical bone, is the most commonly affected site, whereas maxillary involvement is less common in the maxillofacial area [11].

3. DISCUSSION

Hyperparathyroidism was first diagnosed by Sylvanus, while Recklinghausen was credited with the first description of the associated bone changes in 1891 [7]. In 1933, Jaffe coined the term "brown tumour" to describe the osteolytic and cellular lesions in the bone secondary to hyperparathyroidism [8].

Brown tumours are non-neoplastic lesions resulting from abnormal bone metabolism in hyperparathyroidism. Bone involvement is a late manifestation of hyperparathyroidism and includes classic skeletal lesions such as bone resorption, bone cysts, brown tumours and generalised osteopenia. Brown tumour is a kind of giant cell lesion and is so named because of its friable red-brown appearance resulting from vascularity, haemorrhage and haemosiderin deposits [7].

Symptoms can occur at any age; however, the disease is more common in persons older than 50 years [12]. These lesions are three times more frequent in women aged over 50 years. The present case occurred in maxilla in 46-year old female and was asymptomatic.

The histopathological features of brown tumour are suggestive but not sufficient enough to establish the diagnosis or differentiation from other giant cell lesion such as central giant cell granuloma, giant cell tumour, giant cell reparative granuloma, osteoblastoma, chondroblastoma, aneurysmal bone cyst and cherubism [6]. In the present case, the histopathological features resembled reparative giant cell granuloma but the diagnosis of Brown tumour associated with primary hyperparathyroidism was established in view of the clinical, radiographical and laboratory reports. Unless a brown tumour secondary to hyperparathyroidism is considered in the

differential diagnosis of a giant cell bony lesion, its diagnosis would be delayed or missed [6]. With brown tumours becoming less common, an increasingly high index of suspicion is required [6]. They are often asymptomatic and sometimes may be the first impending sign of an underlying previously undiagnosed endocrine disorder as in the present case.

Treatment should commence with treatment of underlying hyperparathyroidism which in turn results in complete resolution. Controlling hyperparathyroidism is mandatory and may be done by carrying out total parathyroidectomy [11]. This is the most logical treatment. However, controversy still persists regarding the course of management of bony lesions postparathyroidectomy. Smith and Bradley agreed to the fact that parathyroidectomy was sufficient to cause the bony lesions to regress [13]. Smith et al. [14] believed that the bony lesions regress with time postparathyroidectomy. Kennet and Pollock stated that surgical intervention should be performed after parathyroidectomy, because spontaneous regression may take more than 5 years [15]. Knezevic et al however reported a case, where the bony lesions resolved within six months postparathyroidectomy [16]. Similar case was reported by Silverman et al. [17]. Literature reveals that age of the patient and the size of the lesion influence the spontaneous regression of the bony lesions postparathyroidectomy [16,17,18]. Kennet & Pollock and Yamazaki et al. however, did combined parathyroidectomy with curettage and enucleation of the jaw lesions [15,19]. Daniels, therefore recommended that in cases where resolution is slow or growth continues to progress in spite of parathyroidectomy, local curettage or enucleation should be carried out [11]. Our patient was a 46-year old female patient with the large lesion measuring around 3 X 2.5 cm. The below-mentioned protocol is followed for the management of present case- parathyroidectomy, follow-up of around 1 year, imaging of the lesions and excision and curettage of the maxillo-mandibular swellings.

Prognosis depends on delay in diagnosis and rapid parathyroidectomy [20].

4. CONCLUSION

Resection is not the only answer for maxillo-mandibular swellings. Before contemplating

resection, the underlying undiagnosed systemic diseases need to be ruled out, so as to prevent surgical defect of the jaws resulting in esthetic and functional deformities.

CONSENT

The authors declare that 'written informed consent was obtained from the patient (or other approved parties) for publication of this case report and accompanying images'.

ETHICAL APPROVAL

It is not applicable.

COMPETING INTERESTS

Authors have declared that no competing interests exist.

REFERENCES

1. Triantafillidou K, Zouloumis L, Karakinaris G. Brown tumors of the jaws associated with primary or secondary hyperparathyroidism. A clinical study and review of the literature. *Am J Otolaryngol.* 2006;27:281-6.
2. Qari FA. Brown tumor in a patient with ectopic mediastinal parathyroid adenoma: A case report. *Saudi Dent J.* 2014;26: 74-7.
3. Marcocci C, Cianferotti L, Cetani L. Bone disease in primary hyperparathyroidism. *Ther Adv Musculoskel Dis.* 2012;4:357-68.
4. Selvi F, Cakarer S, Tanakol R, et al. Brown tumour of the maxilla and mandible: A rare complication of tertiary hyperparathyroidism. *Dentomaxillofac Radiol.* 2009;38:53-8.
5. Nicola DD, Stefano C, Michele F, et al. Brown tumour in a patient with secondary hyperparathyroidism resistant to medical therapy: Case report on successful treatment after subtotal parathyroidectomy. *Int J Endocrinol;* 2009. Article ID 827652, 3 pages. DOI: 10.1155/2009/827652
6. Hannah T, Jones JO, Akoh JA. Maxillary brown tumour: Unusual presentation of parathyroid carcinoma. *JEMDSA.* 2011;16: 111-4.
7. Neville BW, Damm DD, Allen CM, et al. *Oral & maxillofacial pathology*, third ed. St. Louis, WB Saunders. 2009;325-32.

8. Tunali S, Celik HH, Uslu SS, et al. Scanning electron microscopic observation of the brown tumor of head of mandible. Saudi Med J. 2005;26(5):856-8.
9. Proimos E, Chimona TS, Tamiolakis D, et al. Brown tumor of the maxillary sinus in a patient with primary hyperparathyroidism: A case report. J Med Case Rep. 2009;3:7495. DOI: 10.4076/1752-1947-3-7495
10. Thompson NW, Eckhauser F, Harness J. The anatomy of primary hyperparathyroidism. Surg. 1982;92:814-7.
11. Daniels JS. Primary hyperparathyroidism presenting as a palatal brown tumor. Oral Surg Oral Med Oral Pathol Oral Radiol Endod. 2004;98:409-13.
12. Huang BK, Chu YK. Multiple brown tumors mimicking bone metastasis: A case report. Ann Nucl Med Sci. 2010;23:227-33.
13. Smith AC, Bradley JC. Non-surgical management of hyperparathyroidism of the jaws. J Oral Maxillofac Surg. 1987;45:176-81.
14. Smith BR, Fowler CB, Svane TJ. Primary hyperthyroidism presenting as a peripheral giant cell granuloma. J Oral Maxillofac Surg. 1988;46:65-9.
15. Kennet S, Pollock H. Jaw lesions in familial hyperparathyroidism. Oral Surg Oral Med Oral Pathol Oral Radiol Endod. 1971;31:502-10.
16. Knezevic G, Uglesic V, Kobler P, et al. Primary parathyroidism: Evaluation of different treatments of jaw lesions based on case reports. Br J Oral Maxillofac Surg. 1991;29:185-7.
17. Silverman S, Ware WH, Gillooly C. Dental aspects of hyperparathyroidism. Oral Surg Oral Med Oral Pathol Oral Radiol Endod. 1968;26:184-9.
18. Kar DK, Gupta SK, Agarwal A, et al. Brown tumor of the palate and mandible in association with primary hyperparathyroidism. J Oral Maxillofac Surg. 2001;59:1352-1354.
19. Yamazaki H, Ota Y, Aoki T, et al. Brown tumor of the maxilla and mandible: Progressive mandibular brown tumor after removal of parathyroid adenoma. J Oral Maxillofac Surg. 2003;61:719-22.
20. Mahfoudhi M, Khamassi K, Battikh AG, et al. Brown tumor of the maxilla revealing primary hyperparathyroidism. Int J Clin Med. 2015;6:252-6.

© 2016 Kumar et al.; This is an Open Access article distributed under the terms of the Creative Commons Attribution License (<http://creativecommons.org/licenses/by/4.0>), which permits unrestricted use, distribution, and reproduction in any medium, provided the original work is properly cited.

Peer-review history:
The peer review history for this paper can be accessed here:
<http://sciencedomain.org/review-history/13434>