



## What is better in percutaneous nephrolithotomy – Prone or supine? A systematic review

David K.-C. Mak, Yuko Smith, Noor Buchholz & Tamer El-Husseiny

To cite this article: David K.-C. Mak, Yuko Smith, Noor Buchholz & Tamer El-Husseiny (2016) What is better in percutaneous nephrolithotomy – Prone or supine? A systematic review, Arab Journal of Urology, 14:2, 101-107, DOI: [10.1016/j.aju.2016.01.005](https://doi.org/10.1016/j.aju.2016.01.005)

To link to this article: <https://doi.org/10.1016/j.aju.2016.01.005>



© 2016 Arab Association of Urology



Published online: 05 Apr 2019.



Submit your article to this journal [↗](#)



Article views: 833



View related articles [↗](#)




View Crossmark data [↗](#)



## Arab Journal of Urology (Official Journal of the Arab Association of Urology)

www.sciencedirect.com



### STONES/ENDOUROLOGY REVIEW

# What is better in percutaneous nephrolithotomy – Prone or supine? A systematic review



David K.-C. Mak <sup>a</sup>, Yuko Smith <sup>b</sup>, Noor Buchholz <sup>c</sup>, Tamer El-Husseiny <sup>d,\*</sup>

<sup>a</sup> University Hospitals of North Midlands NHS Trust, Stoke-on-Trent, UK

<sup>b</sup> University Hospitals Birmingham NHS Foundation Trust, Birmingham, UK

<sup>c</sup> Sobeh's Vascular and Medical Center Dubai, UAE, Honorary Consultant Urologist Luton and Dunstable NHS Trust, UK

<sup>d</sup> Imperial College Healthcare NHS Trust, London, UK

Received 25 November 2015, Received in revised form 19 January 2016, Accepted 24 January 2016  
Available online 4 March 2016

#### KEYWORDS

PCNL;  
Prone;  
Supine;  
Stones

#### ABBREVIATIONS

PCNL, percutaneous nephrolithotomy;  
RCT, randomised control trial;  
SFR, stone-free rate

**Abstract Objective:** To review the literature reporting the technique of percutaneous nephrolithotomy (PCNL) and outcomes for prone and supine PCNL, as PCNL is an established treatment for renal calculi and both prone and supine PCNL have been described, but there has been much debate as to the optimal position for renal access in PCNL.

**Methods:** A review of the medical literature was conducted using the PubMed database to identify relevant studies reporting on prone and supine PCNL published up until July 2015. Only publications in English were considered. Search terms included 'supine', 'prone', 'percutaneous nephrolithotomy', 'PCNL' and 'randomised controlled trial'. Articles relevant to the particular aspect of PCNL discussed were selected.

**Results:** In all, 30 articles were included in the literature review. Nine of these articles were of Level 1 Evidence as graded by the Oxford System of Evidence-based Medicine.

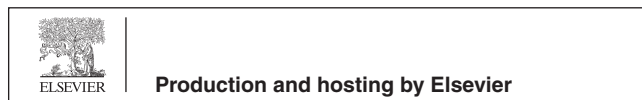
**Conclusion:** The present systematic review highlights the benefits and disadvantages of supine and prone PCNL. The published data on supine and prone PCNL have shown no significant superiority of either approach. Whether prone or supine PCNL is optimal, remains a debatable topic.

© 2016 Arab Association of Urology. Production and hosting by Elsevier B.V. This is an open access article under the CC BY-NC-ND license (<http://creativecommons.org/licenses/by-nc-nd/4.0/>).

\* Corresponding author at: Imperial College Healthcare NHS Trust, Charing Cross Hospital, Fulham Palace Rd, London W6 8RF, UK. Tel.: +44 7824188706.

E-mail address: [tamer.el-husseiny@imperial.nhs.uk](mailto:tamer.el-husseiny@imperial.nhs.uk) (T. El-Husseiny).

Peer review under responsibility of Arab Association of Urology.



## Introduction

Since its first description by Fernstrom and Johansson in 1976 [1], percutaneous nephrolithotomy (PCNL) has become the standard endoscopic treatment for large and complex renal calculi, replacing open surgical removal. Traditionally, the prone position was considered the only position to obtain renal access due to increased concerns of colonic and vascular injury associated with alternative positions.

In 1987, Valdivia Uriá et al. [2] presented the supine PCNL and described the advantages of this ‘simplified’ technique. Over two decades later, interest in supine PCNL has only just begun to rise significantly. A study by the Endourological Society found that 80.3% of patients were operated in the prone position compared with 19.7% in the supine position [3].

Variations of the PCNL technique, including mini-PCNL, ultra-mini-PCNL and tubeless-PCNL, have been described with the aim of reducing patients’ morbidity.

There is still controversy over the optimal position and technique to perform PCNL, and an overall consensus has yet to be reached. We review prone and supine PCNL and their benefits and disadvantages.

## Methods

The PubMed database was searched to include articles published up until July 2015. A combination of the following keywords was used: ‘supine’, ‘prone’, ‘percutaneous nephrolithotomy’, ‘PCNL’ and ‘randomised controlled trial’. Articles published in English were included in the literature review.

The authors independently selected relevant articles through abstract screening pertinent to the aspect of PCNL being analysed. Randomised, non-randomised comparative studies and case series were included in the review. There were only four randomised control trials (RCTs) comparing supine and prone PCNL. **Table 1** provides a summary of the Level of Evidence of selected articles according to the Oxford System for Evidence-based Medicine.

Information was extracted from relevant articles and described where relevant under headings of different aspects of PCNL discussed below.

## Discussion

### *Patient positioning*

Prone PCNL involves posterior renal access through Brodel’s avascular line, allowing for minimal kidney bleeding and the avoidance of visceral injuries. Ureteric catheter insertion is initially undertaken cystoscopically

**Table 1** Number of articles reviewed according to Oxford System for Evidence-based Medicine.

Level of Evidence	Number of selected articles
1	9
2	14
3	0
4	6
5	1

with the patient placed in the lithotomy position, and then retrograde pyelography can be performed.

The patient is then moved into the prone position, which can be hazardous to the patient and adds to the operative time. Turning the patient prone from a supine position risks cervical spine injury due to excessive neck movement and musculoskeletal complications, e.g. brachial plexopathies, hoarseness due to vocal cord compression, and myelic lesions. Therefore, care must be taken when rolling the patient, ensuring a neutral neck alignment. In addition, direct pressure to the periorbital region of the eye can lead to vision loss, due to increased intraocular pressure and subsequent decreased perfusion pressure to the optic nerve and retinal thrombosis [4]. In order, to reduce musculoskeletal complications, different devices have been used to improve patient positioning, such as the Montreal mattress and ProneView® protective helmet system [5].

Modified prone positions, such as an oblique prone or prone split-leg position, permit concomitant access to the upper urinary tract, which has the added benefit of treating potential stone fragment migration into the ureter and aiding endoscopically guided percutaneous renal access [6,7].

The original description of the supine PCNL involves positioning the patient supine with the side of interest on the lateral extreme of the operating table [2]. The ipsilateral flank is elevated with a 1–3 L bag of fluid placed under the lumbar fossa on the operating side. The ipsilateral arm is positioned across the thorax and soft pads applied to pressure points.

In the supine position, retrograde placement of the ureteric catheter, to obtain a retrograde pyelography and aid renal access puncture, is acquired through the easily accessible urethral meatus. As no intraoperative position changes are required in supine PCNL, patient positioning is less demanding and time consuming. The potential risks of musculoskeletal and visual complications that are associated with the prone position are avoided with the supine position. In addition, the supine position provides more comfort for the surgeon who operates in the seated position with the weight of lead shield coats during prolonged procedures, which is not necessarily possible with prone PCNL.

Modifications of the supine position have been described with proposed benefits. The Galdakao-

modified supine position involves placing the ipsilateral leg in an extended position and the contralateral leg in lithotomy after positioning the patient as described by Valdivia [8]. This position affords the ability to perform retrograde ureteroscopy concomitantly with PCNL, which permits percutaneous renal puncture under direct vision (Endovision puncture) and combined retrograde intrarenal stone surgery.

Moraitis et al. [9] described a stone clearance rate of 80% using the Bart's modified lateral position. Patients are placed in the lithotomy position with the ipsilateral hemipelvis tilted upward 45° and maintained by a foam wedge; the torso is then turned to the contralateral side with the shoulders perpendicular to the operating table. The ipsilateral lower limb is flexed and relatively adducted after the lateral rotation of the torso, with the contralateral lower limb remaining fully abducted.

#### *Anaesthetic considerations*

The prone position represents a difficult challenge to the anaesthetist. When positioning a patient in the prone position, there are potential significant cardiovascular changes that must be considered. As a result of decreased venous return, reduced left ventricular compliance due to increased thoracic pressure and direct effects on arterial filling, the cardiac index of the patient is reduced in the prone position [10]. Decreased cardiac output, venous stasis, and thromboembolic events are all recognised complications of the prone position.

In addition, the prone position can be associated with limitation of respiratory movement, which has implications for the obese and patients with respiratory conditions [11]. However, some studies have shown improvement in functional residual capacity in the prone position, in both healthy and obese patients [12,13].

Careful monitoring of endotracheal tube position is another concern for the anaesthetist on transitioning to the prone position. Endotracheal tubes can easily kink or be displaced on moving. The prone position can also pose problems in those patients undergoing loco-regional anaesthesia. If conversion to general anaesthesia is required perioperatively, airway access can prove to be difficult.

The supine position can be considered less of an anaesthetic challenge given that the cardiopulmonary changes seen with the prone position are avoided, and there is easy and rapid access to the airway.

Khoshrang et al. [14] analysed haemodynamic, electrolyte, and metabolic changes during and after prone and supine PCNL. They found significantly less haemodynamic changes in patients undergoing supine PCNL, namely less hypotension and less fluid absorption. Supine PCNL may thus be more advantageous than prone PCNL in reducing cardiovascular complications through more stable haemodynamic changes.

#### *Collecting system access*

Percutaneous access into the intrarenal collecting system using biplanar fluoroscopy and/or ultrasonography is a critical step in PCNL. The underlying principle of percutaneous access is taking advantage of Brodel's bloodless line, which is the perfect point of renal entry avoiding vascular injury [15]. Posterior and anterior calyces are used as a site of entry, with the former being preferred. Entry through the papilla, along the axis of the calyx, aligns access with the infundibulum, which not only reduces risk of vascular injury, but also allows for efficient use of the nephroscope and reduces the need for excessive torque on instruments.

Upper pole punctures are ideal, as it is in line with the long axis of the kidney, permitting access to the renal pelvis superiorly, lower pole, and proximal ureter. However, most urologists generally avoid upper pole access as a supracostal approach is usually required, which increases the risk of pneumothorax. A subcostal approach between the inferior border of the 12th rib and superior aspect of the posterior iliac crest is preferred. The prone position provides a greater distance between these two points, which may improve success in collecting system access.

The prone position potentially offers further advantages in reducing the risk of visceral organ injury through the lateral rotation of the liver and spleen away from possible puncture sites. With the observation of greater caudal displacement of the kidneys during inspiration in the prone position, improved access to the upper pole has been proposed [16].

In the supine position, a longer access tract is required and the kidneys have more mobility within the retroperitoneum, which could make renal access more challenging. In addition, a longer tract may limit nephroscope mobility and exert more torque on the renal parenchyma.

An important benefit of the supine position over the prone position is the potentially reduced radiation exposure. As the puncture site is more lateral with supine PCNL, the surgeon's hands are further away from the fluoroscopic X-ray tube and are exposed to less radiation. In prone PCNL, the surgeon stands in close proximity to the patient, which possibly subjects them to more radiation than with supine PCNL [17].

Comparisons of the technical aspects of prone and supine PCNL have shown equivalent puncture success rates [18]. Shoma et al. [17] reported that although most of renal punctures were undertaken through posterior calyces in both approaches, anterior calyceal punctures were more frequent with supine PCNL. Subcostal and supracostal punctures were feasible in both types of approach. They found that anteromedial movement of the kidney was more evident with the supine position, which could potentially result in increased trauma to the kidney on dilatation.

Radiological analysis of anatomical variations between the prone and supine positions has shown the prone position to be associated with significantly shorter nephrostomy tract length and more potential access sites, which may improve percutaneous renal access success and safety [19].

Simultaneous retrograde flexible ureteroscopy can facilitate percutaneous puncture to gain precise antegrade renal access (Endovision). This can be performed in the prone and supine positions, but is more easily performed in the Galdakao-modified supine position [20,21]. Another important advantage of supine PCNL is that the downward slope of the access tract facilitates the spontaneous exit of many stone fragments.

### PCNL outcomes

To date there have been few randomised trials comparing the outcomes of supine and prone PCNL. Four prospective RCTs have shown comparable outcomes with both approaches (Table 2).

De Sio et al. [22] randomised 75 patients with single or multiple renal stones to prone and supine PCNL treatment groups. However, patients with complete staghorn calculi or stones in multiple calyces were excluded. Patient demographics and stone characteristics were similar in both groups. There were no significant differences evident in length of hospital stay, stone-free rates (SFRs) or complications rates. Operative times were significantly longer in the prone PCNL group.

A similar RCT was conducted by Falahatkar et al. [23], but did include patients with partial and complete staghorn stones. Patients in the supine and prone PCNL groups had similar patient and stone characteristics. Similar results were seen with comparable SFRs and a shorter operative time in the supine group. Although complication rates were similar in both groups, more patients in the supine group required blood transfusion than those in the prone group (27.5% vs 7.5%).

Significantly different SFRs were reported in a RCT by Wang et al. [24], where patients were enrolled to PCNL in either the prone or modified supine position. There was a significantly lower stone clearance rate (73.3% vs 88.7%) and a higher frequency of second procedures required (18.3% vs 6.5%) in the supine group compared with the prone group. The authors did highlight that the X-ray equipment (UROSCOP Access) used for supine PCNL was not mobile and did not allow surgeons to radiologically image the operating area, which could hinder detection of stone remnants at the time of the procedure. Similar to the other studies, significantly shorter operative times were found with supine PCNL.

The most recent RCT by Al-Dessoukey et al. [25], not only compared safety and efficacy of supine and prone PCNL, but also their effects on anaesthetic parameters. Like the earlier RCTs, the results showed equivalent SFRs and complication rates, and significantly shorter operative time and hospital stay for supine PCNL. In addition, the supine PCNL had significantly less of an effect on respiratory and cardiovascular status, which

**Table 2** Prospective RCTs comparing prone and supine PCNL.

Variable	De Sio et al. [22]		Falahatkar et al. [23]		Wang et al. [24]		Al-Dessoukey et al. [25]	
	Supine	Prone	Supine	Prone	Supine	Prone	Supine	Prone
No. of patients	39	36	40	40	60	62	101	102
<i>Mean (range)</i>								
BMI, kg/m <sup>2</sup>	28 (24–30)	26 (23–30)	25.6	26.3	24 (21–28)	25 (20–28)	27.2	26.9
Stone diameter, cm	3.4 (2.5–5.1)	3.3 (2.7–4.5)	4.06	4.03	–	–	3.68	3.93
Stone volume, mL	–	–	–	–	3.1 (1.6–5.8)	3.0 (1.8–6)	–	–
Operative time, min*	43 (25–120)	68 (55–140)	74.7	106.9	88 (55–180)	78 (45–150)	86.2	111.7
<i>Calyx puncture, n (%)</i>								
Lower	32 (82)	28 (78)	27 (67.5)	22 (55)	48 (80)	46 (74.2)	–	–
Middle	7 (18)	8 (27)	2 (5)	3 (7.5)	12 (20)	16 (25.8)	–	–
Upper	0	0	3 (7.5)	1 (2.5)	0	0	–	–
Multiple	0	0	8 (20)	14 (35)	–	–	–	–
SFR, %	88.7	91.6	80	77.5	73.3	88.7	–	–
<i>Second procedure, n (%)</i>								
2nd PCNL	0	0	–	–	6 (10)	0	–	–
ESWL	4 (10.2)	2 (5.6)	–	–	5 (8.3)	4 (6.5)	–	–
URS	0	0	–	–	–	–	–	–
Mean (range) hospital stay, days	4.3 (2.2–8.4)	4.1 (2.4–7.8)	3.33	3.05	8.4 (6–12)	8.2 (6–11)	2.1	3.4
Complications, %	20.5	13.9	27.5	30	28.3	32.3	–	–

ESWL, extracorporeal shockwave lithotripsy; URS, ureterorenoscopy.

\* Statistically significantly different supine vs prone.

could potentially benefit patients with cardiac or respiratory problems.

At the time of writing, three meta-analyses comparing supine and prone PCNL have been published [26–28]. Two of the meta-analyses included two prospective RCTs and two case–control studies, and concluded that prone and supine PCNL offered comparable SFRs and complication rates, and length of hospital stay [26,27]. These two meta-analyses calculated SFRs of 83.4% and 81.6% with the prone position and 84.5% and 83.5% with supine PCNL. Short operative times were found with supine PCNL.

In contrast, Zhang et al. [28] included more studies in their meta-analysis and found significantly better SFRs with the prone position in contrast to supine (77.3% vs 72.9%; odds ratio 1.36; 95% CI 1.19–1.56;  $P < 0.001$ ). They suggested that the difference in results to previous meta-analyses could be a result of a larger number of studies included in the analysis and the heterogeneity in the stone-free assessment of studies.

As previously highlighted, concomitant retrograde ureteroscopy is a potential advantage of supine PCNL. Calyces that are otherwise not accessible via the percutaneous tract can be more easily reached with concomitant flexible ureteroscopy. In addition, irrigation of the calyces is facilitated and stone fragments are prevented from descending into the ureter. Comparable SFRs have been reported with endoscopic combined intrarenal surgery. Scoffone et al. [21] reported SFRs of 81.9% after the first combined procedure with a complication rate of 38.6%. Although, 33.1% of patients included in the study had multiple or staghorn calculi, the mean stone size was 23.8 mm, which is not as high as other published PCNL studies.

### Complications

Visceral injury whilst establishing a percutaneous tract into the renal collecting system is a dangerous but rare complication of PCNL. Hopper et al. [29] evaluated colonic position in relation to the kidneys in the supine and prone positions using CT. A retrorenal colon was found in 1.9% of supine patients and 10.0% in prone patients, mainly adjacent to the lower renal pole. They hypothesised that 4.7% of prone patients had retrorenal colons, which could have implications for renal procedures. Similarly, based on CT analysis, Tuttle et al. [30] found that the colon was located in the path of a lower pole renal puncture in 15% of prone and 6% of supine patients. Prone PCNL may therefore increase the risk of colonic perforation.

AslZare et al. [31] reported a 0.2% incidence of colonic perforation in their 18-year experience of prone PCNL. All patients who sustained colonic injury were treated conservatively and resulted in complete healing of fistulae. Another study of >5000 prone PCNL

reported a 0.3% colonic injury rate and found that patient age and the presence of a horseshoe kidney were risk factors for colon injury but not laterality or the level of the percutaneous tract [32].

Early series of supine PCNL reported no colonic perforation [33]. No visceral injuries have been reported with supine PCNL.

Bleeding can occur during any step of a PCNL. Injury to the main renal vessels is uncommon and has been reported to occur in <0.5% of cases [34]. Renal capsular or renal parenchymal bleeding can result from initial percutaneous access and tract dilatation. Chichakli et al. [35] retrospectively analysed postoperative CT scans of patients who had undergone PCNL within 5 days, and found that nearly one-third of patients had evidence of perinephric haematomas. However, the presence of haematomas was not found to be associated with an increased rate of clinically relevant complications. Only 0.1% of patients with perinephric haematomas required blood transfusion. Advances in techniques and equipment have reduced overall blood transfusion rates for PCNL. Similar blood transfusion rates have been reported in contemporary series of both supine and prone PCNL. Valdivia Uriá et al. [33] reported a 0.8% blood transfusion rate in their 557 supine PCNL patient series, whilst a 0.06% blood transfusion rate in 1338 prone PCNL patients was reported by Duvdevani et al. [36]. Of the available RCTs, no significant differences in blood transfusion rates were reported in the prone or supine position [22–25].

Advocates of supine PCNL have suggested that postoperative fever and sepsis is reduced by the theoretical decrease in pyelovenous back flow resulting from the improved drainage of irrigation fluid around the nephroscope in the supine position [37]. However, no statistically significant difference in the rates of postoperative pyrexia or sepsis has been found in the prone and supine positions.

### Special considerations

#### *Morbidly obese patients*

Performing prone PCNL in the morbidly obese patient can compromise respiratory function and affect venous return. In addition, percutaneous access to the pelvicalyceal system can prove to be more difficult in obese patients. Despite such challenges, El-Assmy et al. [38] reported comparable SFRs and complication rates in obese patients undergoing prone PCNL compared with non-obese patients.

To date, there are no RCTs evaluating prone and supine PCNL in the obese patient. As previously mentioned, the supine position offers potential advantages with regard to cardiopulmonary respiratory compromise. Manohar et al. [39] described their experience of

supine PCNL in morbidly obese patients. They concluded that supine PCNL is effective in obese patients and has the added advantage of the option of simultaneous ureteroscopy to prevent stone migration and improved access to stone bearing calyces to achieve high SFRs.

#### Patients with spinal deformities

Goumas-Kartalas and Montanari [40] published the results of their retrospective study on PCNL using either the prone or supine positions in patients with spinal deformities. The principal factors influencing the complexity of performing PCNL in such patients were respiratory dysfunction, problems in positioning and stabilising patients, and profound anatomical variations. They concluded that supine PCNL offered more advantages for the comfort of the patient, protection of cardiorespiratory function, and the possibility to perform more easily a simultaneous combined ureteroscopic approach; however, the prone position, if achievable with the patient's body habitus, might offer a wider space for the percutaneous access.

#### Conclusions

The published data on supine and prone PCNL have shown no significant superiority of either approach but comparable SFRs and complication rates. There are too few prospective randomised studies to recommend one position over the other and further studies are required. Whilst the optimal access to PCNL still remains a controversial issue, potential advantages of each position for the patient and surgeon are recognised. Until one approach is proven to be superior, it is important for surgeons to have experience in both prone and supine PCNL. Selection of position for PCNL should be based on surgeon preference and patient characteristics.

#### Funding

None.

#### Conflicts of interest

None.

#### References

- [1] Fernstrom I, Johansson B. Percutaneous pyelolithotomy: a new extraction technique. *Scand J Urol Nephrol* 1976;**10**:257–9.
- [2] Valdivia Uria JG, Lachares Santamaria E, Villarroja Rodríguez J, Taberner Llop J, Abril Baquero G, Aranda Lassa JM. Percutaneous nephrolithotomy: simplified technic (preliminary report). *Arch Esp Urol* 1987;**40**:177–80.
- [3] Kamphuis GM, Baard J, Westendarp M, de la Rosette JJ. Lessons learned from the CROES percutaneous nephrolithotomy global study. *World J Urol* 2015;**33**:223–33.
- [4] Walick KS, Kragh Jr JE, Ward JA, Crawford JJ. Changes in intraocular pressure due to surgical positioning: studying potential risk for postoperative vision loss. *Spine* 2007;**32**:2591–5.
- [5] Papatsoris A, Masood J, El-Husseiny T, Maan Z, Saunders P, Buchholz NP. Improving patient positioning to reduce complications in prone percutaneous nephrolithotomy. *J Endourol* 2009;**23**:831–2.
- [6] Khan F, Borin JF, Pearle MS, McDougall EM, Clayman RV. Endoscopically guided percutaneous renal access: “seeing is believing”. *J Endourol* 2006;**20**:451–5.
- [7] Borin JF. Prone retrograde laser lithotripsy facilitates endoscope-guided percutaneous renal access for staghorn calculi: two scopes are better than one. *J Endourol* 2008;**22**:1881–3.
- [8] Ibarluzea G, Scoffone CM, Cracco CM, Poggio M, Porpiglia F, Terrone C, et al. Supine valdivia and modified lithotomy position for simultaneous anterograde and retrograde endourological access. *BJU Int* 2007;**100**:233–6.
- [9] Moraitis K, Philippou P, El-Husseiny T, Wazait H, Masood J, Buchholz N. Simultaneous antegrade/retrograde upper urinary tract access: Bart's modified lateral position for complex upper tract endourologic pathologic features. *Urology* 2012;**79**:287–92.
- [10] Edcombe H, Carter K, Yarrow S. Anaesthesia in the prone position. *Br J Anaesth* 2008;**100**:165–83.
- [11] Valdivia-Uria JG, Valer J, Villarroja S, López JA, Bayo A, Lanchares E, et al. Why is percutaneous nephroscopy still performed with the patient prone? *J Endourol* 2009;**4**:269–72.
- [12] Pelosi P, Croci M, Calappi E, Cerisara M, Mulazzi D, Vicardi P, et al. The prone positioning during general anesthesia minimally affects respiratory mechanics while improving functional residual capacity and increasing oxygen tension. *Anesth Analg* 1995;**80**:955–60.
- [13] Pelosi P, Croci M, Calappi E, Mulazzi D, Cerisara M, Vercesi P, et al. Prone positioning improves pulmonary function in obese patients during general anaesthesia. *Anesth Analg* 1996;**83**:573–83.
- [14] Khoshrang H, Falahatkar S, Ilat S, Akbar MH, Shakiba M, Farzan A, et al. Comparative study of hemodynamics, electrolyte and metabolic changes during prone and complete supine percutaneous nephrolithotomy. *Nephrourol Mon* 2012;**4**:622–8.
- [15] Miller NL, Matlaga BR, Lingeman JE. Techniques for fluoroscopic percutaneous renal access. *J Urol* 2007;**178**:15–23.
- [16] Ray AA, Chung DG, Honey RJ. Percutaneous nephrolithotomy in the prone and prone-flexed positions: anatomic considerations. *J Endourol* 2009;**23**:1607–14.
- [17] Shoma AM, Eraky I, El-Kenawy MR, El-Kappany HA. Percutaneous nephrolithotomy in the supine position: technical aspects and functional outcome compared with the prone technique. *Urology* 2002;**60**:388–92.
- [18] Rana AM, Bhojwani JP, Junego NN, Das Bhagia S. Tubeless PCNL with patient in supine position: procedure for all seasons? – with comprehensive technique. *Urology* 2008;**71**:581–5.
- [19] Duty B, Waingankar N, Okhunov Z, Ben Levi E, Smith A, Okeke Z. Anatomical variation between the prone, supine, and supine oblique positions on computed tomography: implications for percutaneous nephrolithotomy access. *Urology* 2012;**79**:67–71.
- [20] Grasso M, Lang G, Taylor FC. Flexible ureteroscopically assisted percutaneous renal access. *Tech Urol* 1995;**1**:39–43.
- [21] Scoffone CM, Cracco CM, Cossu M, Grande S, Poggio M, Scarpa RM. Endoscopic combined intrarenal surgery in Gal-dakao-modified supine valdivia position: a new standard for percutaneous nephrolithotomy. *Eur Urol* 2008;**54**:1393–403.
- [22] De Sio M, Autorino R, Quarto G, Calabrò F, Damiano R, Giugliano F, et al. Modified supine versus prone position in percutaneous nephrolithotomy for renal stones treatable with a single percutaneous access: a prospective randomized trial. *Eur Urol* 2008;**54**:196–202.
- [23] Falahatkar S, Moghaddam AA, Salehi M, Nikpour S, Esmaili F, Khaki N. Complete supine percutaneous nephrolithotripsy

- comparison with the prone standard technique. *J Endourol* 2008;**22**:2513–7.
- [24] Wang Y, Wang Y, Yao Y, Xu N, Zhang H, Chen Q, et al. Prone versus modified supine position in percutaneous nephrolithotomy: a prospective randomised study. *Int J Med Sci* 2013;**10**:1518–23.
- [25] Al-Dessoukey AA, Moussa AS, Abdelbary AM, Zayed A, Abdallah R, Elderwy AA, et al. Percutaneous nephrolithotomy in the oblique supine lithotomy position and prone position: a comparative study. *J Endourol* 2014;**28**:1058–63.
- [26] Liu L, Zheng S, Xu Y, Wei Q. Systematic review and meta-analysis of percutaneous nephrolithotomy for patients in the supine versus prone position. *J Endourol* 2010;**24**:1941–6.
- [27] Wu P, Wang L, Wang K. Supine versus prone position in percutaneous nephrolithotomy for kidney calculi: a meta-analysis. *Int Urol Nephrol* 2011;**43**:67–77.
- [28] Zhang X, Xia L, Xu T, Wang X, Zhong S, Shen Z. Is the supine position superior to the prone position for percutaneous nephrolithotomy (PCNL)? *Urolithiasis* 2014;**42**:87–93.
- [29] Hopper KD, Sherman JL, Luethke JM, Ghaed N. The retrorenal colon in the supine and prone patient. *Radiology* 1987;**162**:443–6.
- [30] Tuttle DN, Yeh BM, Meng MV, Breiman RS, Stoller ML, Coakley FV. Risk of injury to adjacent organs with lower-pole fluoroscopically percutaneous nephrostomy: evaluation with prone, supine and multiplanar reformatted CT. *J Vasc Interv Radiol* 2005;**16**:1489–92.
- [31] AslZare M, Darabi MR, Shakiba B, Gholami-Mahtaj L. Colonic perforation during percutaneous nephrolithotomy: an 18-year experience. *Can Urol Assoc J* 2014;**8**:323–6.
- [32] El-Nahas AR, Shokeir AA, El-Assmy AM, Shoma AM, Eraky I, El-Kenawy MR, et al. Colonic perforation during percutaneous nephrolithotomy: study of risk factors. *Urology* 2006;**67**:937–41.
- [33] Valdivia Uria JG, Valle Gerhold J, López López JA, Villarroya Rodriguez S, Ambroj Navarro C, Ramirez Fabián M, et al. Technique and complications of percutaneous nephroscopy: experience with 557 patients in the supine position. *J Urol* 1998;**160**:1975–8.
- [34] Mousavi-Bahar SH, Mehrabi S, Moslemi MK. Percutaneous nephrolithotomy complications in 671 consecutive patients a single-center experience. *J Urol* 2011;**8**:271–6.
- [35] Chichakli R, Krause R, Voelzke B, Turk T. Incidence of perinephric haematoma after percutaneous nephrolithotomy. *J Endourol* 2008;**22**:1227–32.
- [36] Duvdevani M, Razvi H, Sofer M, Beiko DT, Nott L, Chew BH, et al. Contemporary percutaneous nephrolithotripsy: 1585 procedures in 1338 consecutive patients. *J Endourol* 2007;**21**:824–9.
- [37] Duty B, Okhunov Z, Smith A, Okeke Z. The debate over percutaneous nephrolithotomy positioning: a comprehensive review. *J Urol* 2011;**186**:20–5.
- [38] El-Assmy AM, Shokeir AA, El-Nahas AR, Shoma AM, Eraky I, El-Kenawy MR, et al. Outcome of percutaneous nephrolithotomy: effect of body mass index. *Eur Urol* 2007;**52**:199–205.
- [39] Manohar T, Jain P, Desai M. Supine percutaneous nephrolithotomy: effective approach to high-risk and morbidly obese patients. *J Endourol* 2007;**21**:44–9.
- [40] Goumas-Kartalas I, Montanari E. Percutaneous nephrolithotomy in patients with spinal deformities. *J Endourol* 2010;**24**:1081–9.