

Accuracy and complications of pedicle screw insertion for lumbar and thoracolumbar fractures

Parisa Azimi¹, Sohrab Shahzadi¹, Andia Shahzadi²

¹ Functional Neurosurgery Research Center, Shohada Tajrish Hospital, Shahid Beheshti University of Medical Sciences, Tehran, Iran

² University of Toronto, Ontario, Canada

ABSTRACT

Background: The accuracy of pedicle screw placement is essential for lumbar and thoracolumbar spine fracture fixation.

Purpose: The aim of the present study was to assess the accuracy of the pedicle screw placement with conventional C-arm fluoroscopy-guided in these patients.

Methods: A retrospective review identified patients who underwent operative management with thoracolumbar instruments at our hospital between June 2012 and August 2013. Clinical data were acquired from medical records and final screw positions were graded based on a classification of Gertzbein and Robbins.

Results: A total of 216 pedicle screws in 52 patients (34 males, mean age 32.6±5.8 years) were evaluated. They were instrumented with transpedicular posterior fixation technique within 72 hours. The follow-up time was 6.1 months (ranging from 1 to 14 months). The screws were graded A (n=43 [19.9%]), B (n=89 [41.2%]), C (n=62 [28.7%]), D (n=21 [9.7%]), and E (n=1 [0.5%]). One of the screws was revised on the second day after surgery due to screw malposition.

Conclusion: Based on existing facilities, the findings showed that the pedicle instrumentation screws with transpedicular posterior fixation technique in patients with lumbar and thoracolumbar fractures can be done with acceptable complication rate. However, more advanced equipment as CT navigation (O-arm) is recommended for higher accuracy.

Keywords: Lumbar and thoracolumbar fracture; Spine instrumentation; Accuracy; Pedicle screw placement

ICNSJ 2014; 1 (2):61-64

www.journals.sbmu.ac.ir/neuroscience

Correspondence to: Parisa Azimi, MD; Functional Neurosurgery Research Center, Shohada Tajrish Hospital, Tajrish Sq, Tehran, Iran; E-mail: parisa.azimi@gmail.com; Tel: +98(21)22749204; Fax: +98(21)88265188

Received: October, 7, 2014

Accepted: October, 16, 2014

INTRODUCTION

The most common fractures of the spine occur in the thoracic and lumbar spine or at the connection of the two. These fractures are usually caused by severe injury to the spine. A severe thoracolumbar fracture may require surgery as pedicle screw insertion to return the bones to their normal position, but it may be associated with complications such as screw mal positioning¹. In addition, in spinal fusion surgery, the accuracy with which screws are inserted in the pedicle has a direct effect on the surgical outcome and is essential for lumbar

and thoracolumbar spine fracture fixation². Due to the impact of misaligning one or more pedicle screws can directly influence patient safety, a number of navigational and trajectory verification approaches as fluoroscopic C-arm and CT navigation (O-arm) have been introduced and assessed in the literature to provide some degree of guidance to the surgeon²⁻³. One of the accuracy of screw placement was introduced by Gertzbein and Robbins⁴. Therefore, the aim of the present study is to assess the accuracy of the pedicle screw placement with conventional C-arm fluoroscopy-guided in these patients

based on Gertzbein and Robbins scale and outcome compared to O-arm image-guided pedicle screw insertion.

MATERIAL AND METHODS

Patients and data collection

We retrospectively reviewed patients who had received surgery for lumbar and thoracolumbar fracture. The post-operative results studied in 52 of the patients between

June 2012 and August 2013 at a teaching hospital, Sanandaj, Iran.

Demographics data were extracted from case records. There were no limitations on patient selection with regard to the types of lumbar and thoracolumbar spine fracture, number of fractures levels, age or other characteristics. The exclusion criteria were prior lumbar spine surgery and spinal anomalies. Patients underwent transpedicular posterior fixation technique.

The outcome measurement was screw accuracy. CT scans with axial, coronal, and sagittal reconstructions were obtained in all patients at postoperative, and the accuracy of screw placement was assessed based on the Gertzbein and Robbins scale⁴⁻⁵ (from Grade A to E: A, perfect intrapedicular localization; E, > 6 mm deviation from ideal intrapedicular trajectory; Figure 1). Screws graded A and B are clinically acceptable, screws graded C, D, and E have a significant deviation from the intended trajectory⁴.

Statistical analysis

The statistical software was SPSS for windows (Version 17.0, SPSS Inc, Chicago, Illinois, USA).

Ethics

The research was approved by the Ethics Committee of Sanandaj University of Medical Sciences, Sanandaj, Iran.

RESULTS

A total of 216 pedicle screws in 52 patients (34 males, mean age 32.6±5.8 years, ranging from 18 to 71 years) were evaluated. All of patients were underwent transpedicular posterior fixation technique in single stage within 72 hours. The follow-up time was 6.1 months (ranging from 1 to 14 months). Pedicle and screw diameters are shown in table 1.

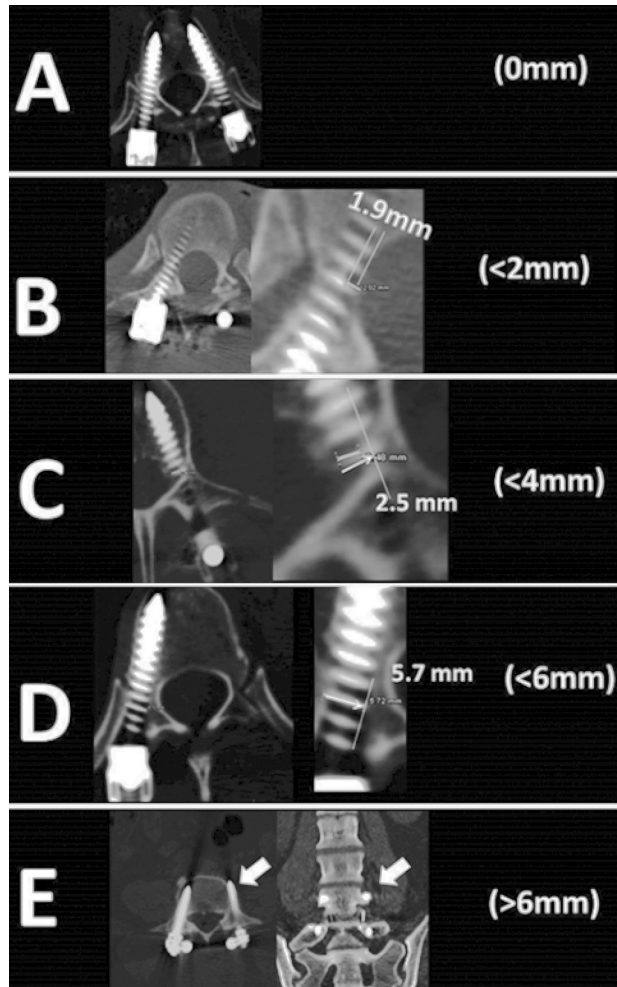


Figure 1. Computed tomography scans demonstrating the Gertzbein and Robbins classification. The grading system reflects the deviation of the screw from the “ideal” intrapedicular trajectory. The grades are as follows: A is an intrapedicular screw without breach of the cortical layer of the pedicle. B describes a screw that breaches the cortical layer of the pedicle but does not exceed it laterally by more than 2 mm. C and D reflect a penetration of less than 4 and 6 mm, respectively. We attributed Grade E to screws that do not pass through the pedicle or that, at any given point in their intended intrapedicular course, breach the cortical layer of the pedicle in any direction by more than 6 mm. Note that the screw that was marked with “D” has a deviation of more than 4 mm from the intrapedicular directory. However, in this case of a thoracic pedicle screw this deviation was intentional. Because of the very thin pedicles, we used the in-out-in technique to allow for optimal screw purchase in this case. [Derived from reference number 4 with permission].

Table 1. Pedicle and screw sizes.

Segment	No. of Screws	Diameter*	
		Pedicle	Screw
T-9	18	6.1 (1.1)	4.6 (0.21)
T-10	28	6.4 (1.2)	5.6 (0.11)
T-11	36	6.7 (1.2)	5.5 (0.15)
T-12	38	6.9 (1.1)	5.6 (0.21)
L-1	28	7.2 (2.1)	4.7 (0.41)
L-2	18	7.4 (1.7)	5.6 (0.6)
L-3	26	8.6 (1.3)	6.3 (0.3)
L-4	8	9.7 (1.8)	6.5 (0.2)
L-5	8	11.5 (2.2)	6.3 (0.3)
S-1	8	16.3 (3.9)	6.6 (0.4)
Overall	216	7.6 (1.2)	5.6 (0.3)

*Pedicle and screw diameters are provided in millimeters as mean (SD).

The mean duration of surgery was 197±34 minutes. Blood loss during surgery was 621±367 minutes. The overall length of stay at hospital was 10.9±4.8 days. The screws were graded A (n=43 [19.9%]), B (n=89 [41.2%]), C (n=62 [28.7%]), D (n=21 [9.7%]), and E (n=1 [0.5%]). One of the screws was revised on the second day after surgery due to screw malposition.

DISCUSSION

This study evaluated the radiographic results in 216 pedicle screws in 52 patients who underwent transpedicular instrumentation for lumbar and thoracolumbar spine injuries. Based on existing facilities, the findings showed that the pedicle instrumentation screws with transpedicular posterior fixation technique in these patients can be done with acceptable complication rate. Although, the fluoroscopic C-arm presented in this study is an acceptable procedure to benefit operative treatment of these patients, more advanced equipment as CT navigation (O-arm) is recommended for higher accuracy.

Transpedicular screw fixation offers three-column stabilization and has become an innovative treatment of thoracic and lumbar fractures. The documented overall complication rate for the use of pedicle screws ranges between 21% and 27%⁶, which is inline to our findings. In approximately 10% of cases, intraoperative complications established into neurological impairment from causes such as nerve root injury, pedicle fracture, dural tear injury with cerebrospinal fluid leakage, vascular injury, visceral injury from screw over penetration, and screw malposition³. In this study screw malposition was considered, and show that 38.9% of patients had grade C, grade D or grade E based on Gertzbein and Robbins scale. Schatlo et al. reported that in the SpineAssist robotic system group, a perfect trajectory (A) had observed in 83.6% of screws⁴. The remaining screws had graded B (7.8%), C (3.7%), D (1.6%), and E (0.8%) that only 6.1% had grade C, D and E. Accordingly, O-arm systems and SpineAssist robotic systems can be help to the accurate placement of pedicle screws.

There are several benefits of O-arm image-guided pedicle screw insertion in thoracic and lumbar spine fractures. The radiation exposure to surgeons, patients and operating room staff is reduced when intraoperative C-arm fluoroscopy is not used. The operating time and the risk of infection are also reduced, as well³. In addition, some authors concluded that the accuracy of pedicle screw placement is improved and the risk of resulting complications from screw misplacement is reduced

with intraoperative computer guidance^{3,7,8}. Overall, CT-based computer-assisted navigation surgery allows spine surgeons to more accurately insert pedicle screws for thoracic and spine deformities^{7,9-13}. However, due to financial problems we have not O-arm system at our center.

There were some limitations in our study. Due to retrospective design, we were limited as to the data that was available for extraction. More studies are needed to investigate the differences between long- and short-term follow-up of operative outcomes in these patients.

CONCLUSION

Based on existing facilities, the findings showed that the pedicle instrumentation screws with transpedicular posterior fixation technique in patients with lumbar and thoracolumbar fractures can be done with acceptable complication rate. However, more advanced equipment as CT navigation (O-arm) is recommended for higher accuracy.

Disclosure

None

Competing interests

The authors declare that they have no competing interests.

ACKNOWLEDGMENT

The authors thank the staff of the Neurosurgery Unit at Bassett Hospital, Sanandaj, Iran.

REFERENCES

1. Gaines RW Jr. The use of pedicle-screw internal fixation for the operative treatment of spinal disorders. *J Bone Joint Surg Am.* 2000;82-A(10):1458-76.
2. Manbachi A, Cobbold RS2, Ginsberg HJ3. Guided pedicle screw insertion: techniques and training. *Spine J.* 2014;14(1):165-79.
3. Fan Chiang CY, Tsai TT, Chen LH, Lai PL, Fu TS, Niu CC, et al. Computed tomography-based navigation-assisted pedicle screw insertion for thoracic and lumbar spine fractures. *Chang Gung Med J.* 2012;35(4):332-8.
4. Schatlo B, Molliqaj G, Cuvinciuc V, Kotowski M, Schaller K, Tessitore E. Safety and accuracy of robot-assisted versus fluoroscopy-guided pedicle screw insertion for degenerative diseases of the lumbar spine: a matched cohort comparison. *J Neurosurg Spine.* 2014;20(6):636-43.
5. Gertzbein SD, Robbins SE. Accuracy of pedicular screw placement in vivo. *Spine (Phila Pa 1976).* 1990;15:11-14.

6. Heini P, Scholl E, Wyler D, Eggli S. Fatal cardiac tamponade associated with posterior spinal instrumentation. A case report. *Spine (Phila Pa 1976)*. 1998;23:2226-30.
7. Laine T, Lund T, Ylikoski M, Lohikoski J, Schlenzka D. Accuracy of pedicle screw insertion with and without computer assistance: a randomised controlled clinical study in 100 consecutive patients. *Eur Spine J*. 2000;9:235-40.
8. Amiot LP, Lang K, Putzier M, Zippel H, Labelle H. Comparative results between conventional and computer-assisted pedicle screw installation in the thoracic, lumbar, and sacral spine. *Spine (Phila Pa 1976)*. 2000;25:606-14.
9. Merloz P, Tonetti J, Pittet L, Coulomb M, Lavallee S, Sautot P. Pedicle screw placement using image guided techniques. *Clin Orthop Relat Res*. 1998;354:39-48.
10. Schwarzenbach O, Berlemann U, Jost B, Visarius H, Arm E, Langlotz F, Nolte LP, Ozdoba C. Accuracy of computer-assisted pedicle screw placement. An in vivo computed tomography analysis. *Spine (Phila Pa 1976)*. 1997;22:452-8.
11. Kotani Y, Abumi K, Ito M, Minami A. Improved accuracy of computer-assisted cervical pedicle screw insertion. *J Neurosurg* 2003;99:257-63.
12. Kotani Y, Abumi K, Ito M, Takahata M, Sudo H, Ohshima S, et al. Accuracy analysis of pedicle screw placement in posterior scoliosis surgery: comparison between conventional fluoroscopic and computer-assisted technique. *Spine (Phila Pa 1976)*. 2007;32:1543-50.
13. Youkilis AS, Quint DJ, McGillicuddy JE, Papadopoulos SM. Stereotactic navigation for placement of pedicle screws in the thoracic spine. *Neurosurgery*. 2001;48:771-8.