

Endoscopic Surgery for Third Ventricular Colloid Cysts in the Absence of Hydrocephalus: a feasibility study

Guive Sharifi, Mehrdad Hosseinzadeh Bakhtevvari, Omidvar Rezaei, Reza Jabbari

Department of neurosurgery, Loghman Hakim hospital, ShahidBeheshti University of Medical Sciences, Tehran, Iran

ABSTRACT

Purpose: The aim of this study was to investigate the feasibility and effectiveness of endoscopic neurosurgery for patients with third ventricular colloid cysts without ventriculomegaly.

Methods: Seventy-one patients with third ventricular colloid cysts were identified and recruited to this study. Eighteen of these patients did not have concomitant hydrocephalus and underwent primary endoscopic surgery for cyst resection. The surgical technique, the success rate, and patients' outcome were assessed and compared with 53 hydrocephalic patients who underwent similar procedures.

Results: The ventricular compartments were successfully cannulated and gross total resection of the colloid cysts was achieved in all patients. There were no operative complications related to the endoscopic procedure. Two patients required subsequent intervention for hydrocephalus. The success rate for endoscopic surgery in non-hydrocephalic patients was similar to its value in patients with hydrocephalus.

Conclusion: Endoscopic resection of third ventricular colloid cyst in patients without hydrocephalus seems to be feasible, effective and not contraindicated.

Keywords:

ICNSJ 2014; 1 (2):73-77

www.journals.sbmu.ac.ir/neuroscience

Correspondence to: Mehrdad Hosseinzadeh Bakhtevvari, MD; Department of Neurosurgery, Loghman Hakim Hospital, Shahid Beheshti University of Medical Sciences, Tehran-Iran; E-mail: mehrdaada@yahoo.com; Tel / Fax: +98(21)55414065

Received: September 25, 2014 **Accepted:** October 16, 2014

INTRODUCTION

Colloid cysts are benign developmental lesions that commonly occur at the anterior roof of the third cerebral ventricle close to the foramen of Monro. They account for about 0.5-2 percent of all intracranial and 15-20 percent of all intraventricular tumors^{1,2}. Despite their rare occurrence, colloid cysts are important clinical problems as they interfere with the cerebrospinal fluid (CSF) outflow, giving rise to prominent hydrocephalus, acute deterioration, and, rarely, sudden death³. Therefore, early detection and treatment are highly recommended^{3,4}.

The optimal management of colloid cysts has always been a debatable issue over the past decades. Treatment options include CSF diversion procedures, stereotactic aspiration, microsurgical resection, and

endoscopic removal of colloid cysts⁵. The transcallosal or transcortical craniotomy has been the traditional approach for microsurgical resection of colloid cysts for many years. Indeed, because of its capability of accomplishing a complete resection, the microsurgical approach has been considered as the gold standard technique for treatment of colloid cysts. However, it is associated with significant morbidity and prolonged postoperative hospital stay^{5,6}, even though some studies favored microsurgery over other techniques^{2,7,8}. On the other hand, endoscopic resection of colloid cysts has been associated with lower risk of complications, less operative morbidity and postoperative shunt dependency, reduced operative time, shorter hospital stay, and lower infection rate, but with slightly higher recurrence rate^{5,9-12}.

Total extirpation of colloid cysts using endoscopic neurosurgery has frequently been reported since the advent of modern endoscopic equipments^{13,14}. Endoscopic neurosurgery has been considered as the first-line approach for removal of colloid cysts in the presence of ventriculomegaly^{15,16}. But, it usually is avoided in patients without hydrocephalus owing to presumed difficulties with ventricular cannulation and intraventricular navigation, and the perceived risk of greater morbidity. However, some reports exist on the viability of endoscopic approach for removal of colloid cysts and other brain tumors, as well as biopsy of peri- and intraventricular brain tumors¹⁷⁻²⁰. Here we present and review our experience in endoscopic treatment of patients with third ventricular colloid cysts and discuss the treatment outcomes and complications particularly in patients with normal-size ventricles.

METHODS AND MATERIALS:

Patient selection

From September 2003 to September 2010, 96 patients with third ventricular colloid cysts were treated in Loghman Hakim Hospital, ShahidBeheshti Medical University, Iran. Of these patients, 25 underwent open craniotomy and 71 patients were treated with endoscopic surgery. From the latter population, 18 (~25%, 8 men and 10 women, aged 22-56 years, mean age 35.3 years) did not have radiographic indication of ventriculomegaly at presentation (Figure 1-3), and the other 53 (~75%, 24 men and 29 women, aged 30-62 years, mean age 43.1 years) presented with hydrocephalus. Radiographic imaging were performed for a variety of reasons, including headaches, nausea, and incidental findings such as a minor closed head injury, altered cognition, and visual symptoms. To ascertain the accuracy of the preliminary judgment regarding the normal size of ventricular system in patients with no apparent hydrocephalus, a two-dimensional measurement of the frontal Evan's ratio was

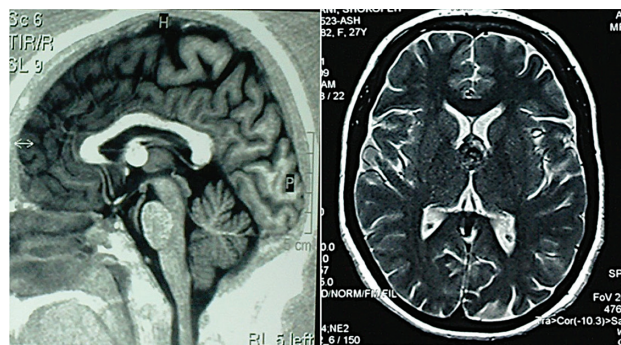


Figure 1. MRI shows hard and big colloid cyst without hydrocephalus.

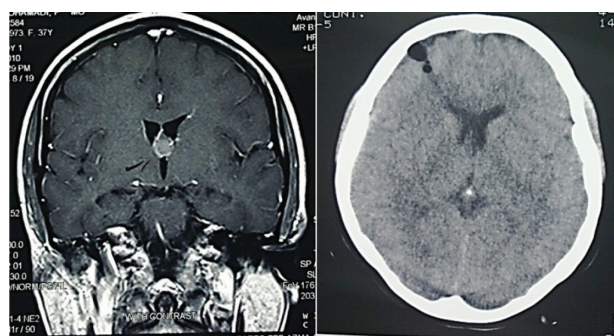


Figure 2. MRI shows hard and small colloid cyst (left). Post op CT scan (right).

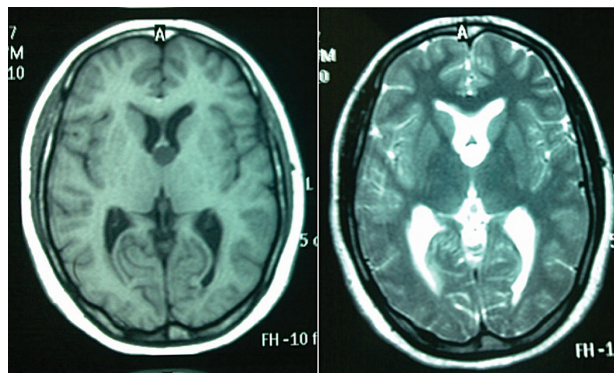


Figure 3. MRI shows medium sized colloid cyst without hydrocephalus.

performed on preoperative magnetic resonance imaging (MRI) scans by an independent radiologist. A value of less than 0.30 was considered as the normal-size ventricle. The Research Deputy of ShahidBeheshti University of Medical Sciences granted approval for the review of medical records and conducting this study.

Endoscopic surgery

All procedures were performed using general anesthesia in patients laid in supine position with the head elevated to approximately 30 degrees above the horizontal plane to minimize CSF egress through the endoscope. All patients received intravenous antibiotic prophylaxis before skin incision. An access point offering the most direct intraventricular path to the tumor site was selected on the nondominant side of the head, 5-6 cm anterior to coronal suture at hairline, and 3-4 cm lateral to midline. A 4-cm linear skin incision was made parallel to the midline at the selected entry site and a 1-cm diameter burr hole was then created on the frontal bone to permit access to the ventricular space. The dura was incised, a ventricular catheter was introduced into the anterior horn of the lateral ventricle, and upon CSF return, controlled gradual insufflations of the ventricular system were performed with lactated Ringer's solution (Figure 4). Subsequently,

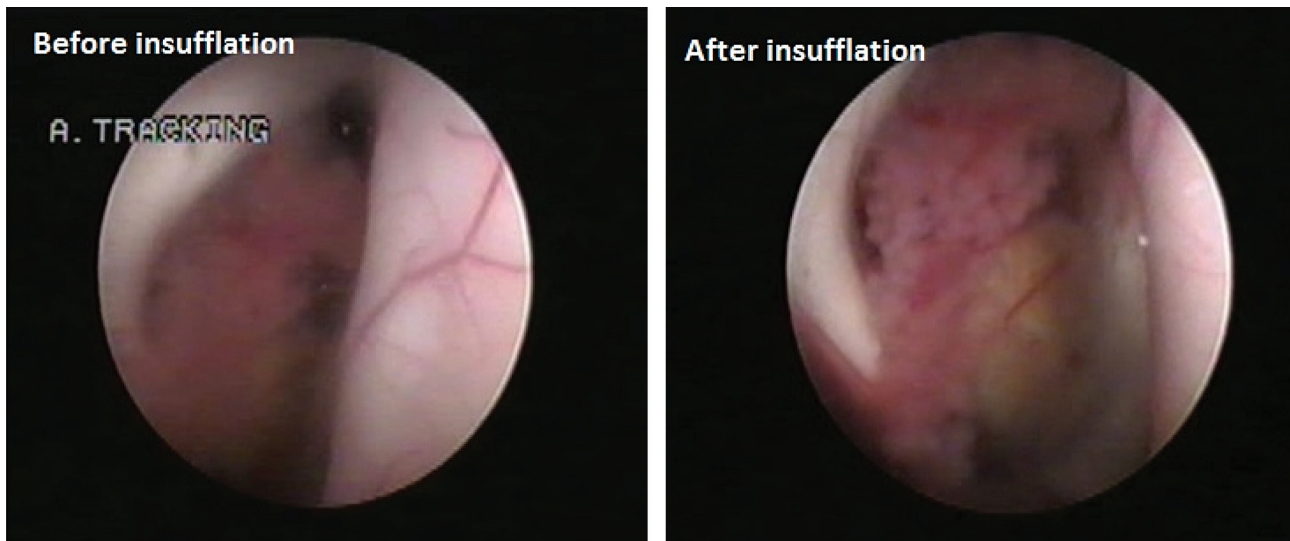


Figure 4. Endoscopic views of the ventricular space before (left) and after (right) insufflation

the access catheter was substituted with either a 0-degree or rarely a 30-degree rigid lens endoscope (Karl Storz, Tuttlingen, Germany) with an outside diameter of 6 mm and a 2-mm working channel.

When in the lateral ventricle, the endoscope was oriented backward to observe the foramen of Monro, and guided toward the third ventricle through a trajectory parallel the roof of third ventricle, lateral enough to avoid fornix, and medial enough to avoid the head of the caudate (Figure 5).

In patients with normal-sized ventricles, the ventricular space was expanded by closing the portal, and the endoscope was advanced with quick back and forth movements along the long axis to pass safely by the head of caudate and approach the foramen of Monro. Meanwhile, much attention was paid to the patient's hemodynamics with respect to bradycardia or transient hypertension secondary to raised intracranial pressure. The endoscope's head was placed at about 5 mm of the Monro foramen in the middle of the telachoroidea and floor of the anterior horn for no more than 30 s. Then the portal was opened to lower intraventricular pressure with a constant purge through the portal which maintained an intracranial pressure below that of the length of fluid column inside the endoscope (15 cm H₂O). In patients with hydrocephalus, however, there was a wider view, especially for observing column of fornix with no need for ventricular insufflations.

The surgical procedure was similar in patients with and without hydrocephalus. After coagulating choroid plexus with bipolar diathermy, the cyst wall was coagulated and then perforated with a Pury needle or microscissors and

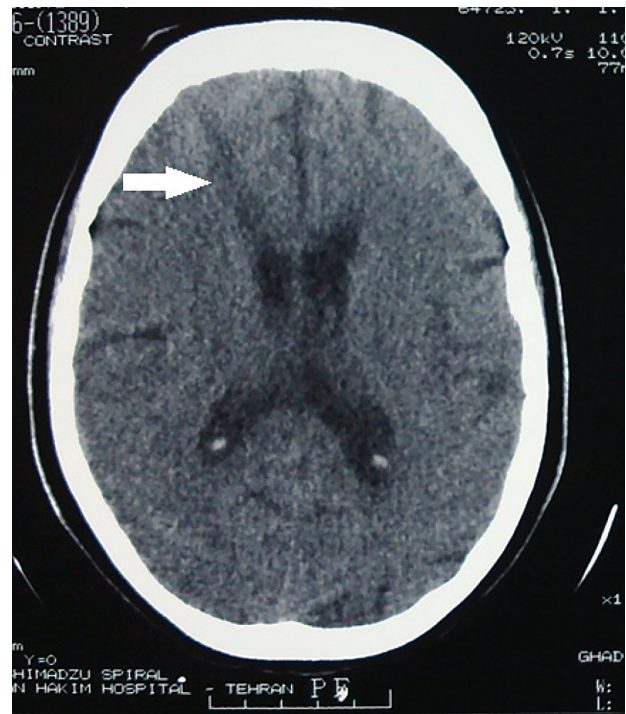


Figure 5. The optimized trajectory for achieving third ventricular colloid cysts is parallel the roof of third ventricle, lateral enough to avoid fornix, and medial enough to avoid the head of the caudate. The arrow points the endoscopic tract.

forceps as appropriate. The cyst content was evacuated with suction aspiration, and the cyst remnants were extirpated with bipolar diathermy and sharp dissection. In some patients, endoscopic third ventriculostomy or septostomy were performed simultaneously. The endoscope was then taken out, a small piece of Gelfoam was placed in the cortical opening, bone powder was

replaced in the burr hole, and the wound was closed in two layers.

RESULTS

The largest cyst diameter in patients treated with endoscopic neurosurgery was 26 mm (Figure 1). Presenting symptoms included headache in 10 patients, and altered cognition, visual symptoms, nausea and incidental findings such as minor closed head injury each in 2 patients. The mean Evan's ratio of the 18 selected patients who considered as with normal-size ventricles was 0.28 ± 0.02 , which was less than the reported normative mean of 0.37.

The intended goal of surgery was evacuation of the whole cyst material under the direct observation through the endoscope during the surgery which was confirmed by lack of any remnants in post-operative CT scan (Figure 6). The surgical objective of total resection of the third ventricular cysts was achieved in all of the 71 patients who underwent the endoscopic surgery including those with or without hydrocephalus (100% success rate). The Fisher's exact test showed that there was no significant difference in achieving the surgical objective between patients with hydrocephalus at presentation and those without hydrocephalus (P value=1).

With respect to operative outcomes, in patients with normal-size ventricles no recognized neurological complications, seizures, infections, or death related to the surgical procedure ensued. Caudate injuries were detected in 2 patients in postoperative CT scans without any neurological deficit. Because of mild intraoperative intraventricular bleedings, externalized ventricular

drains were placed in 6 patients at the time of surgery for postoperative pressure monitoring. All drains were removed until the second postoperative day because of normal intracranial pressures. However, in patients with hydrocephalus, 2 patients needed subsequent shunting since they displayed signs of raised intracranial pressure. There has been no recurrence of colloid cysts in both groups during a mean follow-up period of 44.4 months.

DISCUSSION

Endoscopic surgery is the first-line treatment of third ventricular colloid cysts in the presence of hydrocephalus to decrease morbidity. However, the optimal management of colloid cysts in patients with normal-size ventricles is unclear. In this regard, microsurgery has been reported to have some priorities over other techniques^{2,7,8}, but in the past two decades, endoscopic resection of colloid cysts has also been accomplished in patients without ventriculomegaly^{19,20}. The reason why endoscopic surgery is avoided in patients without hydrocephalus is that the success rate of endoscopic ventricular access would be reduced, in that ventricular cannulation and intraventricular navigation may be difficult¹⁷. In 2005, Souweidane reported the feasibility of performing endoscopic biopsy or resection of intraventricular brain tumors in the absence of ventriculomegaly with no operative complications related to the endoscopic procedure and no need for subsequent intervention for hydrocephalus¹⁹. Moreover, Song et al reported in 2010 that they successfully performed navigation guided neuroendoscopic biopsy in 6 patients with peri- or intraventricular tumors without hydrocephalus¹⁷.

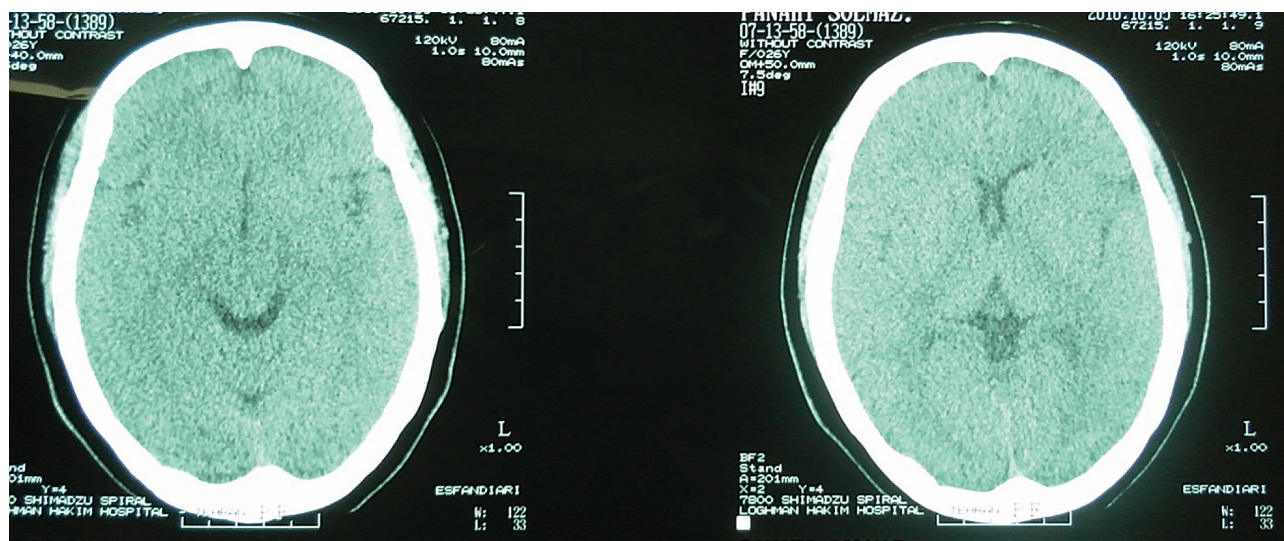


Figure 6. Post-operative CT scan imaging showing no tumor remnant after endoscopic removal of colloid cyst.

Furthermore, Wait et al reported that in their experience, endoscopic removal of colloid cysts was achieved in 15 out of 16 patients without ventriculomegaly, while complication rate was comparable to that of endoscopic surgery in the presence of ventriculomegaly or of open microsurgical resection²⁰.

In the present study we further evaluated the feasibility of performing endoscopic surgery for complete removal of third ventricular colloid cysts in patients with normal-size ventricles. The results of this study showed that total resection of colloid cysts using endoscopic approach was achieved in all of the 18 recruited patients with normal-size ventricles. The patients' outcomes in terms of intraoperative or postoperative complications were also similar to those of the patients with ventriculomegaly. Therefore, since the success rate or the morbidity of endoscopic removal of ventricular colloid cysts did not differ between patients with normal-size ventricles and those with hydrocephalus, it can be proposed that when indications for intraventricular tumor resection are present, the absence of hydrocephalus does not contraindicate an endoscopic approach.

In conclusion, if a highly skillful endoscopic approach is adopted for management of patients with third ventricular colloid cysts and normal-size ventricles, complete low-morbidity removal of such tumors is feasible.

REFERENCES

1. Antunes JL, Louis KM, Ganti SR. Colloid cysts of the third ventricle. *Neurosurgery*. 1980;7(5):450-5.
2. Sampath R, Vannemreddy P, Nanda A. Microsurgical excision of colloid cyst with favorable cognitive outcomes and short operative time and hospital stay: operative techniques and analyses of outcomes with review of previous studies. *Neurosurgery*. 2010;66(2):368-74.
3. de Witt Hamer PC, Verstegen MJ, De Haan RJ, Vandertop WP, Thomeer RT, Mooij JJ, et al. High risk of acute deterioration in patients harboring symptomatic colloid cysts of the third ventricle. *J Neurosurg*. 2002;96(6):1041-5.
4. Desai KI, Nadkarni TD, Muzumdar DP, Goel AH. Surgical management of colloid cyst of the third ventricle--a study of 105 cases. *Surg Neurol*. 2002;57(5):295-302.
5. Grondin RT, Hader W, MacRae ME, Hamilton MG. Endoscopic versus microsurgical resection of third ventricle colloid cysts. *Can J Neurol Sci*. 2007;34(2):197-207.
6. Lewis AI, Crone KR, Taha J, van Loveren HR, Yeh HS, Tew JM, Jr. Surgical resection of third ventricle colloid cysts. Preliminary results comparing transcallosal microsurgery with endoscopy. *J Neurosurg*. 1994;81(2):174-8.
7. Symss NP, Ramamurthi R, Rao SM, Vasudevan MC, Jain PK, Pande A. Management outcome of the transcallosal, transforaminal approach to colloid cysts of the anterior third ventricle: an analysis of 78 cases. *Neurol India*. 2011;59(4):542-7.
8. Shapiro S, Rodgers R, Shah M, Fulkerson D, Campbell RL. Interhemispheric transcallosal subchoroidal fornix-sparing craniotomy for total resection of colloid cysts of the third ventricle. *J Neurosurg*. 2009;110(1):112-5.
9. Wilson DA, Fusco DJ, Wait SD, Nakaji P. Endoscopic Resection of Colloid Cysts: Use of a Dual-Instrument Technique and an Anterolateral Approach. *World Neurosurg*. 2012.
10. Horn EM, Feiz-Erfan I, Bristol RE, Lekovic GP, Goslar PW, Smith KA, et al. Treatment options for third ventricular colloid cysts: comparison of open microsurgical versus endoscopic resection. *Neurosurgery*. 2007;60(4):613-8.
11. Hellwig D, Bauer BL, Schulte M, Gatscher S, Riegel T, Bertalanffy H. Neuroendoscopic treatment for colloid cysts of the third ventricle: the experience of a decade. *Neurosurgery*. 2003;52(3):525-33.
12. Margetis K, Souweidane MM. Endoscopic treatment of intraventricular cystic tumors. *World Neurosurg*. 2013;79(2 Suppl):S19 e1-1.
13. Decq P, Le Guerinel C, Brugieres P, Djindjian M, Silva D, Keravel Y, et al. Endoscopic management of colloid cysts. *Neurosurgery*. 1998;42(6):1288-94.
14. Gaab MR, Schroeder HW. Neuroendoscopic approach to intraventricular lesions. *Neurosurg Focus*. 1999;6(4):e5.
15. Teo C. Complete endoscopic removal of colloid cysts: issues of safety and efficacy. *Neurosurg Focus*. 1999;6(4):e9.
16. Abdou MS, Cohen AR. Endoscopic treatment of colloid cysts of the third ventricle. Technical note and review of the literature. *J Neurosurg*. 1998;89(6):1062-8.
17. Song JH, Kong DS, Seol HJ, Shin HJ. Transventricular Biopsy of Brain Tumor without Hydrocephalus Using Neuroendoscopy with Navigation. *J Korean Neurosurg Soc*. 2010;47(6):415-9.
18. Naftel RP, Shannon CN, Reed GT, Martin R, Blount JP, Tubbs RS, et al. Small-ventricle neuroendoscopy for pediatric brain tumor management. *J Neurosurg Pediatr*. 2011;7(1):104-10.
19. Souweidane MM. Endoscopic surgery for intraventricular brain tumors in patients without hydrocephalus. *Neurosurgery*. 2008;62(6 Suppl 3):1042-8.
20. Wait SD, Gazzeri R, Wilson DA, Abla AA, Nakaji P, Teo C. Endoscopic Colloid Cyst Resection in the Absence of Ventriculomegaly. *Neurosurgery*. 2013;73(1 Suppl Operative):ons39-46; ons46-7.