

Histological Study of the Monosodium Glutamate (MSG) and Root Back Extract of *Rauvolfia vomitoria* on the Kidney of Albino Rats

**Kingsley A. Okon^{1*}, Enobong I. Bassey¹, Gabriel D. Edem¹
and Kufre N. Ekanem¹**

¹*Department of Anatomy, Faculty of Basic Medical Sciences, University of Uyo, Uyo, Nigeria.*

Authors' contributions

This work was carried out in collaboration among all authors. Author KAO designed the study, wrote the study protocol and the first draft of the manuscript. Authors KNE and GDE carried out all laboratories work. Authors KAO and EIB managed the literature searches and edited the manuscript. All authors read and approved the final manuscript.

Article Information

Editor(s):

(1) Dr. Rodolfo Valtuille, Salvador University, Argentina.

Reviewers:

(1) Manuel E. Herrera-Gutierrez, University of Malaga, Spain.

(2) Himanshu Joshi, Graphic Era Hill University, India.

Complete Peer review History: <http://www.sdiarticle4.com/review-history/58959>

Original Research Article

**Received 08 June 2020
Accepted 12 August 2020
Published 22 August 2020**

ABSTRACT

Aim: To provide information on the interactive influence of monosodium glutamate and root back extract of *Rauvolfia vomitoria* on the histology of the kidney.

Methods: Twenty-five (25) albino Wistar rats weighing between 142g to 204g were used for this research. These animals were divided into five (5) groups, containing five (5) rats in each group. Group A which served as control group, group B was administered with 4mg/kg body weight of monosodium glutamate (MSG) for 42 days, group C was administered with 8mg/kg body weight of MSG for 42 days, group D was administered 4mg/kg body weight of MSG for 28 days and also 212.5mg/kg body weight of root back extract of *R. vomitoria* for 14 days and group E was administered with 8mg/kg body weight of MSG for 28 days and also 425mg/kg body weight of root back extract of *R. vomitoria* for 14 days. The administration was done orally twice daily (morning and evening) and lasted for 42 days. After the 42 days the animals were sacrificed by chloroform inhalation anesthesia and the kidneys harvested, fixed in 10% buffered formalin processed and stained with Hematoxylin and Eosin staining technique.

*Corresponding author: E-mail: kingsleyokon407@gmail.com;

Results: At the tested dose, monosodium glutamate was nephrotoxic, evident in the enlargement of the Bowman's space, mild shrinkage of the glomerulus, hemorrhages, and tubular dilatation in group 2 animals treated with 4 mg/kg body weight of monosodium glutamate for 42 days and group 3 treated with 8 mg/kg body weight of MSG for 42 days with the severity increasing with dosage. *Rauvolfia vomitoria* seems to ameliorate this effect as evident in group 4 treated with 4 mg/kg body weight of MSG for 28 days and thereafter, 212.5 body weight root bark extract of *R. vomitoria* for 14 days.

Conclusion: The result shows that monosodium glutamate has a nephrotoxic effect which is relative with the quantity taken while *R. vomitoria* exert some level of ameliorative impact.

Keywords: *Monosodium glutamate; Rauvolfia vomitori; kidney; nephrotoxic.*

1. INTRODUCTION

Monosodium glutamate is a globally used food additive [1]. It is a sodium salt of glutamic acid that has the potential of producing a unique taste which enhance substantial food intake [2]. It is used in the food industries, restaurants and homes. This sodium salt is known to be harmless if consumed in small quantity but prolong use of the salt produces a myriad of toxic effect called the Chinese restaurant syndrome. The syndrome is characterized with sweating, nausea, tightness of chest, headache and burning sensation in the back of the neck [3].

MSG was also seen to significantly increase the gross weight of the heart, altered histological organization of the cardiac muscle, significantly thickened the myocytes and widened the extracellular spaces of the cardiac muscle fibers [4,5].

Rauvolfia vomitoria is a useful medicinal plant used in the management of variety of ailment such as snakebites, fever and nervous disorders [6]. It contains a bioactive carboline alkaloid, alstonine, present in the root and leaf and have anti-cancer activity [7]. The use of plant botanicals for the manufacturing of plant based drugs has greatly increased. This has resulted in the use of ethno-medical and ethno-botanical technique in the validation and manufacturing of plant based drugs [8].

2. MATERIALS AND METHODS

2.1 Experimental Animals

Twenty-five (25) female adult albino Wistar rats were obtained from the Animal House, Faculty of Basic Medical Sciences, University of Uyo and transferred to the Animal House, Department of Pharmacology and Toxicology, Faculty of Pharmacy, University of Uyo, Uyo. The animals were housed and maintained under standard

environmental conditions. The rats were divided into five (5) groups (Groups A, B, C, D and E) containing five (5) rats each. The animals were housed in five labeled wooden cages with wire gauge covers and sawdust as beddings and fed with vital growers mash (Agro Feed) and clean drinking water was provided ad libitum. The rats were kept and bred for weeks in the Animal House, Faculty of pharmacy, University of Uyo, Uyo, which was well ventilated throughout the experimental course.

2.2 Preparation of Monosodium Glutamate

Monosodium glutamate used in this study was purchased from Itam Market, Itam, uyo, Akwa Ibom State and was prepared daily at the concentration of 80g/litre for the period of administration [9,10].

2.3 Plant Material and Authentication

Fresh leaves of *Rauvolfia vomitoria* were obtained from the city of Uyo. They were identified and authenticated by Mrs. E. G. Udoma of the Faculty of Botany, University of Uyo herbarium with voucher number UUPH 46(e) for *Rauvolfia vomitoria*.

2.4 Extract Preparation

The roots were cleaned to remove adhering dirt and sand, the root back removed, air-dried and grinded into powder using a manual blender. Extraction was carried out by macerating and sucking in commercial ethanol for extraction for about 48hours with intermittent agitation and was then filtered and left in the water bath to concentrate.

2.5 Experimental Design

Twenty-five (25) albino wistar rats weighing between 142g to 204g were used for this

research. These animals were divided into five (5) groups containing five (5) rats in each group. Group A which served as control was administered with distilled water, group B was administered with 4mg/kg body weight of monosodium glutamate (MSG) for 42 days, group C was administered with 8mg/kg body weight of MSG for 42 days, group D was administered with 4mg/kg body weight of MSG for 28 days and also 212.5mg/kg body weight of root back extract of *R. vomitoria* for 14 days and group E was administered with 8mg/kg body weight of MSG for 28 days and also 425mg/kg body weight of root back extract of *R. vomitoria* for 14 days. The administration was done orally twice daily (morning and evening) and lasted for 42 days [10].

At the end of the research period, the rats were anaesthetized with chloroform and the abdomen opened using ventro-median incision. The kidneys were removed, cleaned and fixed in 10% formalin and processed for Haematoxylin and Eosin technique.

3. RESULTS AND DISCUSSION

3.1 Histological Findings

Light microscopic evaluation of the kidney in transverse section of the control group revealed normal cytoarchitecture with glomerulus, Bowman's capsule and space intact Figure 1. Section of the kidney in group 2 administered with 4mg/kg body weight of MSG for 42 days showed enlarged Bowman's spaces, shrunken glomerulus, vacuolation and tubular dilation Figure 2. Section of the kidney of group 3 animals administered with 8mg/kg body weight of MSG for 42 days showed eroded glomerulus, severe shrunken glomerulus, severe enlarged Bowman's spaces, degenerated glomerulus Figure 3, while section of the kidney of group 4 animals administered with 4mg/kg body weight of MSG for 28 days and 212.5mg/kg body weight of root back extract of *R. vomitoria* for 14 days showed almost normal glomerulus, Bowman's capsule and spaces Figure 4. Section of the kidney of group 5 animals administered with 8mg/kg body weight of MSG for 28 days and 425mg/kg body weight of root back extract of *R. vomitoria* for 14 days showed eroded glomerulus, shrunken glomerulus and enlarged Bowman's spaces Figure 5, but not as compared to that in Figures. 2 and 3.

The result of sections of the kidney of rats treated with monosodium glutamate and

Rauvolfia Vomitoria root back extract are shown in Figures 1-5.

Monosodium glutamate is a commonly used food additive used to improve taste in modern nutrition [11]. Despite its taste stimulation and appetite enhancement, various researchers had reported that it is toxic to humans and experimental animals.

In this study, the findings on histological changes in rat kidney treated with monosodium glutamate were mostly in conformity with the findings of previous studies. In the present experimental study, some of the sections of kidney tissue showed enlarged Bowman's space, shrunken glomerulus, eroded glomerulus, tubular dilatation and necrosis. Similar findings were observed in studies done by [12,13].

Findings observed in sections of rat kidney treated with 4mg/kg body weight of MSG has early degenerative changes like Glomerular shrinkage, enlarge Bowman's space, vacuolation, tubular dilatation which are in conformity with the studies reported by [14,15].

Some of the sections also showed shrunken glomerulus with swollen Bowman's capsule, eroded glomerulus, vacuolation in glomerulus and necrotic changes in urinary tubules; similar findings are reported by [13]. Group 3 was severely affected than Group 2 showing that high dosage of MSG consumption is highly nephrotoxic.

Animal studies suggest that chronic monosodium glutamate (MSG) intake is capable of inducing kidney damage by oxidative stress. Oxidative stress is caused by the excessive production or a decreased elimination of free radicals in cells, the majority of which are oxygen radicals and other reactive oxygen species (ROS) [16]. Other factors such as nutrition metabolism and several extracellular and intracellular factors such as hormones, cytokines, and detoxification processes are contributive factor to oxidative stress [17]. Therefore, excessive renal metabolism of glutamate as in chronic MSG intake can be a source of reactive oxygen species. Decreased levels of major anti-oxidant enzymes like superoxide dismutase, catalase, glutathione-S-transferase and increased lipid peroxidation have been demonstrated in the kidneys of chronic MSG-exposed rats [18]. Also, high doses of glutamate have been shown to induce significant toxicity in renal culture cells [19].

Farombi [20] indicated in his study that dietary antioxidants had protective potential against oxidative stress induced by MSG, which suggested that reactive oxygen species played an important role in its toxicity. Renal tubular epithelial cells are particularly sensitive to ischemia and toxins. Also, tubules came in contact with toxic chemicals during their excretion and elimination by the kidneys. The loss of polarity of polarized epithelia of proximal convoluted tubules due to its contact with toxins resulted in their ischemia and eventual necrosis. The results of this experiment suggest that the distortion of the cytoarchitectural structures of the kidney could have been associated with functional changes that may have been detrimental to the health status of the animal which may have been due to the interference of MSG on the kidney.

Co-administration of 4mg/kg body weight of MSG and 212.5mg/kg body weight of ethanolic root bark extract of *R. vomitoria* showed normal kidney structures in Figure 4. while the co-administration of 8mg/kg body weight of MSG and 425mg/kg body weight of ethanolic root bark extract of *R. vomitoria* showed abnormal structures in Figure 5. Figure 4 indicates that the extract ameliorate the nephrotoxic effect of monosodium glutamate. This could be attributed to the present of alkaloids, flavonoids and polyphenols present in *R. vomitoria*, which possess an anti-inflammatory and antioxidant properties [21]. Why it is not so in Figure 5 could be as a result of high dosage of MSG (8 mg/kg body weight) given to this group. High dosage intake of MSG (6mg/kg body weight) causes more degenerative and atrophic changes in the cytoarchitectural structure of the kidney [22].

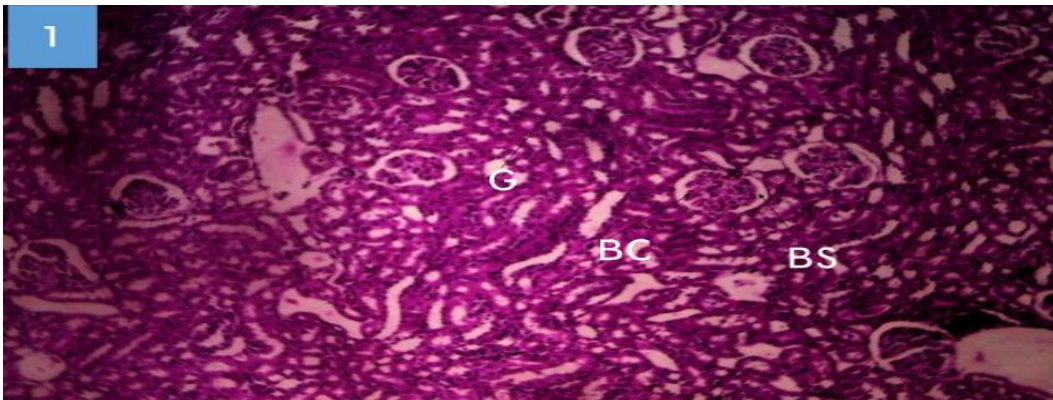


Figure 1. Section of the kidney of Group 1 (control) adult albino rat showing normal cytoarchitecture

G – Glomerulus, BC - Bowman's capsule, BS - Bowman's Space (H & E x100)

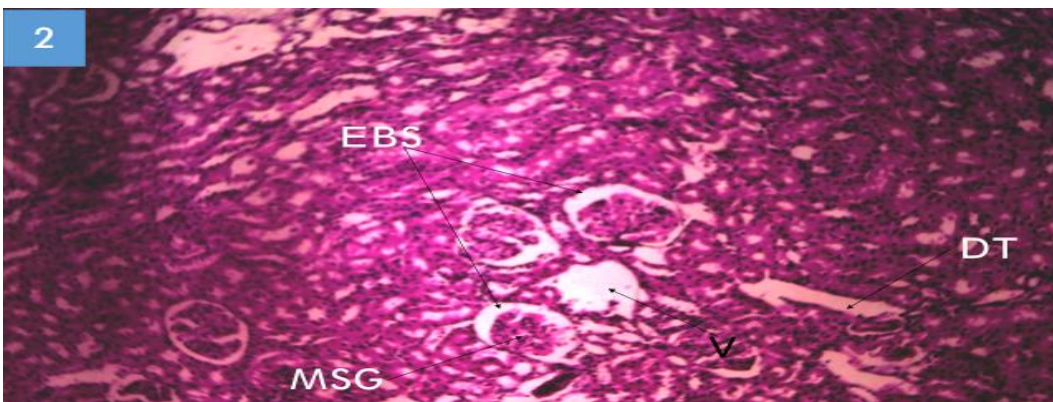


Figure 2. Section of the kidney of group 2 adult albino rat administered with 4 mg/kg of monosodium glutamate (MSG) for 42 days

EBS – Enlarge Bowman's Spaces, MSG – Mild Shrunken Glomerulus, V – Vacuolation, TD – Tubule Dilatation (H & E x100)

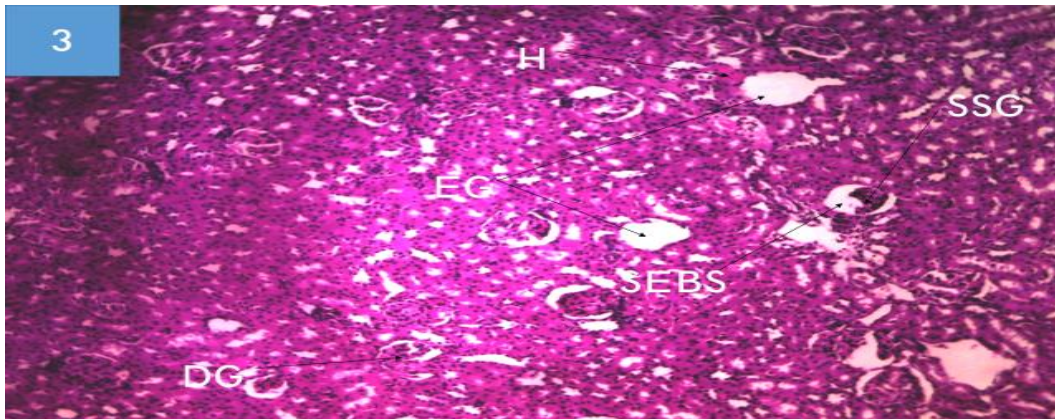


Figure 3. Section of the kidney of group 3 adult albino rat administered with 8 mg/kg of MSG for 42 days

EG – Eroded Glomerulus, SSG – Severe Shrunken Glomerulus, SEBS – Severe Enlarge Bowman's Space, H – Hemorrhage, DG – Degenerated Glomerulus (H & E x100)

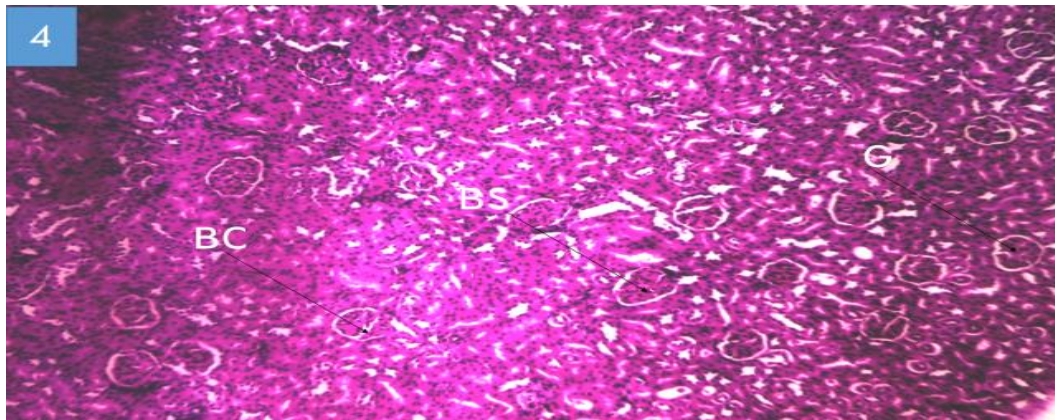


Figure 4. Section of the kidney of group 4 adult albino rat kidney administered with 4 mg/kg of MSG for 28 days and 212.5 mg/kg of *R. vomitoria* for 14 days

G – Glomerulus, BC - Bowman's capsule, BS - Bowman's Space (H & E x100)

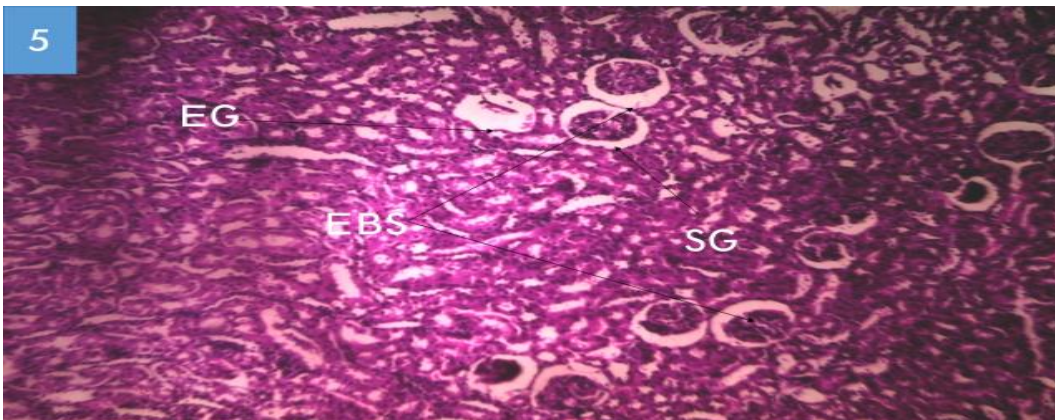


Figure 5. Section of the kidney of group 5 adult albino rat kidney administered with 8 mg/kg of MSG for 28 days and 425 mg/kg of *R. vomitoria* for 14 days

EG – Eroded Glomerulus, SG – Shrunken Glomerulus, EBS – Enlarge Bowman's Space (H & E x100)

Scientific research has identified essential minerals and compounds in plants that are not only required for proper nutrition but are responsible for health maintenance and disease prevention [23]. These health promoting compound are referred to as phytonutrients. *R. vomitoria* contains phytonutrients whose consumption has been associated with reduced risks of cerebral cramps, jaundice, gastrointestinal disorder, hypertension, cardiovascular diseases and insanity [24]. Ezejindu and collugues [25] reported that the leaf extract of *R. vomitoria* has an antioxidant and protective properties that could prevent damage to the kidneys. Stem back aqueous extract of *R. vomitoria* has been reported to contain flavonoid [26]. Flavonoids are well known to possess anti-inflammatory effects. Among the phenolic compounds, flavonoids are known to display anti-inflammatory and anti-oxidant effects by inhibiting lipid peroxidation [21]. The phytochemical analysis of the aqueous extract of *R. vomitoria* contain alkaloids, flavonoids and polyphenols which are responsible for anti-inflammatory properties by the inhibition of lipopolysaccharide-induced nitric oxide (NO). The antioxidant activity of polyphenolic compounds is well known and is mainly due to their redox properties, which play an important role in neutralizing free radicals, quenching singlet and triplet oxygen species or decomposing peroxides [27].

Inflammation and oxidative stress are closely related events, free radicals and reactive oxygen species (ROS) are continuously generated inside the body as a result of exposure to many exogenous drugs and xenobiotics e.g monosodium glutamate. Under normal condition, there is equilibrium between the ROS generated and the antioxidants present as the reactive oxygen species generated are neutralized by endogenous antioxidants [28].

4. CONCLUSION

From the present research, it could be concluded that persistence consumption of high dosage of MSG is highly nephrotoxic, it cause damages to the cytoarchitectural structure of the kidney and that the root bark ethanolic extract of *R. vomitoria* can ameliorate the sub-chronic effect of MSG on the cytoarchitectural structure of the kidney.

CONSENT

It is not applicable.

ETHICAL APPROVAL

Animal ethic Committee approval has been collected and preserved by the author.

COMPETING INTERESTS

Authors have declared that no competing interests exist.

REFERENCES

1. Husarova V, Ostatnikova D. Monosodium glutamate toxic effects and their implications for human intake: A Review JMED Research. 2013;1-12.
2. Kulkarni A, Sundaresan A, Rashid M, Yamamoto S, Karkow F. Application of diet-derived taste active components for clinical nutrition: Perspectives from ancient ayurvedic medical science, space medicine, and modern clinical nutrition. Current Pharmaceutical Design. 2014;20: 2791-2796.
3. Williams A, Woessner K. Monosodium glutamate 'allergy': Menace or myth? Clinical Experimental Allergy. 2009;39: 640-646.
4. Okon K, Jacks T, Amaza D, Tarfa P, Eduitem O. The effect o Monosodium Glutamate (MSG) on the gross weight of the heart of albino rats. Scholars Journal of Applied Sciences. 2013;1(2):44-47.
5. Okon K, Ekanem A, Gabriel D, Martha A. Histological and morphometric studies of the effect of monosodium glutamate (MSG) on the cardiac muscle fibres of adult albino rats. Discovery. 2020;56(289):36-43.
6. Sharma R. Agro-Techniques of medicinal plants; India, Daya Publishing House. 2004;14-24.
7. Demis D, Capodice J, Gorroochum P, Katz A, Buttyan R. Antipostrate cancer act-carboline alkaloid enriched extract from *Rauvolfia vomitoria*. International Journal of Oncology. 2006;29(5):1065-1073.
8. Quah S. Traditional healing system: negotiating science and technology challenges NUS, Singapore, Indigenous knowledge systems. Research and Development Studies. 2003;4 200.
9. Miskowiak B, Partyka M. Effect of neonatal treatment with MSG on thyroid of adult male rats. Histopathology. 1999;14:63-67.
10. Paleaz B, Blazques J, Sanchez A, Amat P. Lectin-Histochemistry and Ultrastruture of microglial response to monosodium

- glutamate-mediated neurotoxicity in the arcuate nucleus. *Histology and Histopathology*. 1999;14:165-174.
11. Beyreuther K, Biesalski H, Fernstrom J, Grimm P, Hammes W. Consensus meeting: monosodium glutamate - An update. *European Journal of Clinical Nutrition*. 2007;61:304-313.
 12. Contini M, Millen N, Riera L, Mahieu S. Kidney and liver functions and stress oxidative markers of monosodium glutamate induced obese rats. *Food and Public Health*. 2012;2(5):168-177.
 13. Onalapo A, Onalapo O, Mosaku T, Akanji O, Abiodun O. Histological study of the hepatic and renal effects of subchronic low dose oral monosodium glutamate in swiss albino mice. *British Journal of Medicine and Medical Research*. 2013; 3(2):294-306.
 14. Schiffman S. Sensory enhancement of foods for the elderly with monosodium glutamate and flavors. *Food Reviews International*. 1998;14(2):321-333.
 15. Nagata M, Suzuki W, Iizuka S, Tabuchi M, Maruyama H, Takeda S, Aburada M, Miyamoto K. Type 2 diabetes mellitus in obese mouse model induced by monosodium glutamate. *Experimental Animal*. 2006;55(2):109-115.
 16. Bashan N, Kovsan J, Kachko I, Ovadia H, Rudich A. Positive and negative regulation of insulin signaling by reactive oxygen and nitrogen species. *Physiological Reviews*. 2009;89(1):27-71.
 17. Corda S, Laplace C, Vicaut E, Duranteau J. Rapid reactive oxygen species production by mitochondria in endothelial cells exposed to tumor necrosis factor- α is mediated by ceramide. *American Journal of Respiratory Cell Molecular Biology*. 2001;24(6):762-768.
 18. Paul M, Abhilash M, Varghese M, Alex M, Nair R. Protective effects of α -tocopherol against oxidative stress related to nephrotoxicity by monosodium glutamate in rats. *Toxicology and Mechanical Methods*. 2012;22(8): 625-630.
 19. Leung J, Ragland N, Marphis T, Silverstein D. NMDA agonists and antagonists induce renal culture cell toxicity. *Medicinal Chemistry*. 2008;4(6):565-571.
 20. Farombi E, Onyema O. Monosodium glutamate induced oxidative damage and genotoxicity in the rat: Modulatory role of vitamin C, vitamin E and Quercetin. *Human Experimental Toxicology*. 2006; 25(5):251-259.
 21. Rotelli A, Guardia T, Juarez A, Enesto R, Pelzer L. Comparative study of flavonoids in experimental models of inflammation. *Pharmacology researches*. 2003;48:601-606.
 22. Eweka A. Histological studies of the effects of monosodium glutamate on the kidney of adult wistar rats. *The Internet Journal of Health*. 2006;6:2.
 23. Molyneux R, Lee S, Gardner D, James L. "Phytochemicals; the good, the bad and the ugly?" *Phytochemistry*. 2007;68(22):2973-2985.
 24. Shavarov Z. The healing powers of herbs with special reference to obstetrics and gynecology. 1965; 43-44.
 25. Ezejindu D, Chienweife K, Uloneme G. The effect of *Rauvolfia vomitoria* extract on liver enzymes of potassium induced hepatotoxicity in adult Wistar rats. *International Journal of Biomedical and Advance Research*. 2013;4(12).
 26. Youmbie D, Paul D, Nkwengoua T, Stephane Z. Anti-inflammatory and anti-oxidant effects of the stem bark aqueous extract of *Rauvolfia vomitoria* (Apocynaceae) in female Wistar rats. *European Journal of Pharmaceutical and Medical Research*. 2015;2(7):64-73.
 27. Rice-Evans C, Miller N, Paganga G. Structure-anti-oxidant activity relationships of flavonoids and phenolic acids in Free radicals. *Journal of Biology and Medicine*. 2010;20:933-956.
 28. Azab S, Abdel-Daim M, Eldahshan O. Phytochemical, cytotoxic, hepatoprotective and anti-oxidant properties of *Delonix regia* leaves extract. *Medicinal Chemistry Researches*. 2013;22:4269-4277.

© 2020 Okon et al.; This is an Open Access article distributed under the terms of the Creative Commons Attribution License (<http://creativecommons.org/licenses/by/4.0>), which permits unrestricted use, distribution, and reproduction in any medium, provided the original work is properly cited.

Peer-review history:

The peer review history for this paper can be accessed here:
<http://www.sdiarticle4.com/review-history/58959>