



# Spinal Subarachnoid Hemorrhage Associated with Spinal Ischemic Stroke in the Thoracic Region of the Spinal Cord – A Case Report

E. Viteva<sup>1\*</sup> and O. Chaneva<sup>1</sup>

<sup>1</sup>Department of Neurology, Plovdiv Medical University, Plovdiv, Bulgaria.

## Authors' contributions

*This work was carried out in collaboration between both authors. Author EV was in charge of the patient during his hospital stay and managed the literature search. Author OC wrote the first draft of the manuscript with assistance from author EV. Both authors read and approved the final manuscript.*

## Article Information

DOI: 10.9734/INDJ/2016/25903

Editor(s):

(1) Pasquale Striano, Pediatric Neurology and Muscular Diseases Unit, University of Genoa, G. Gaslini Institute, Genova, Italy.

Reviewers:

(1) Fatima Mubarak, Aga Khan University, Pakistan.

(2) A. Arboix, University of Barcelona, Catalonia, Spain.

(3) Mario Guidotti, Valduce General Hospital, Como, Italy.

Complete Peer review History: <http://sciencedomain.org/review-history/14205>

Case Study

Received 25<sup>th</sup> March 2016

Accepted 7<sup>th</sup> April 2016

Published 15<sup>th</sup> April 2016

## ABSTRACT

We present a case report of a 69-year old man with spinal ischemic stroke and spinal subarachnoid hemorrhage (sSAH) in the thoracic region. The first complaint was low back pain, which was followed by retention of urine, inferior paraplegia and distal hypesthesia below Th<sub>7-8</sub> dermatome. The diagnosis was confirmed by lumbar puncture, which showed xanthochromic cerebrospinal fluid with erythrocyte- and proteinrachia, and contrast MRI of thoracic region, the latter visualizing two lesions. The intraspinal lesion is hyperintense on T<sub>2</sub> and iso- to hypointense on T<sub>1</sub>, corresponding to an ischemic spinal stroke. The extraspinal lesion is hypointense on all sequences and corresponds to a chronic sSAH. The patient denies traumatic injuries, but is with a history of a regular intake of Acenocumarol for chronic atrial fibrillation. The laboratory investigations at hospital admittance showed that the patient is in a state of hypocoagulability. The applied medications resulted in satisfactory improvement of the neurological symptoms. In our opinion the presented case report is of interest because of the extreme rarity of sSAH, moreover in association with spinal ischemic stroke. The hypocoagulability state is the most probable cause of sSAH, which is later complicated with arterial vasospasm, the latter resulting in spinal ischemic stroke.

\*Corresponding author: E-mail: [eiviteva@abv.bg](mailto:eiviteva@abv.bg);

**Keywords:** Spinal; subarachnoid hemorrhage; ischemic stroke; MRI.

## 1. INTRODUCTION

The spinal origin of subarachnoid hemorrhage has been reported in less than 1% of patients with this type of brain hemorrhage [1]. The most frequent causes of spinal subarachnoid hemorrhage (sSAH) are spinal arterial-venous malformations (AVM), spinal artery aneurysm, primary spinal tumors, metastases, traumatic injuries, coagulopathies and autoimmune vascular diseases [2]. Spontaneous sSAH is extremely rare, 12 cases out of a total number of 69 with sSAH have been described by now [3]. Secondary sSAH is much more frequent compared to spontaneous sSAH [4]. It is usually caused by coagulopathy, hematological diseases, alcohol hepatitis, lumbar puncture, spinal cord traumatic injury, preceding spinal surgery and AVM [5]. The combination of sSAH with spinal ischemic stroke is extremely rare. There is a single case report in literature describing spinal infarction associated with sSAH as a consequence of multiple dissecting aneurysms of spinal arteries [6].

### 1.1 Purpose

A case report with spinal subarachnoid hemorrhage associated with spinal ischemic stroke in the thoracic region of the spinal cord.

## 2. CASE REPORT

A 69-year old patient S.I.H. was admitted to the neuro-intensive care unit of the University hospital "St. George" in Plovdiv, Bulgaria, complaining about low back pain in the last 2 days, significantly relieved at the moment of hospitalization, retention of urine in the last 24 hours, weakness and numbness in the lower extremities in the last 7 hours. There is no disease history about traumatic injuries or vascular malformations. The patient suffers from arterial hypertension, ischemic heart disease, chronic atrial fibrillation, dyslipidemia, diabetes mellitus and diabetic polyneuropathy and benign prostatic hyperplasia.

The clinical manifestations included a syndrome of spinal cord damage in the thoracic region with impairment of 3 functional systems:

- Motor deficit: inferior upper motor neuron paraplegia with muscle hypotonia, (+)

Babinski sign bilaterally, hypo- to areflexia of lower extremities deep tendon reflexes

- Sensory deficit: distal hypesthesia to anesthesia below Th<sub>7-8</sub> dermatome
- Retention of urine and faeces.

Laboratory investigations: at hospital admittance the patient was in a state of hypocoagulability with prothrombin time <5% and INR 14.89, with a history of a regular intake of Acenocumarol for thromboembolic prophylaxis, and without satisfactory monitoring of coagulation.

Full blood count: erythrocytes – 3.89; 3.45; 3.59 (4.5 – 6 x 10<sup>12</sup>/l); hemoglobin – 127; 113; 117 (140 – 180 g/l); hematocrit – 0.366; 0.322; 0.355 (0.400 – 0.540); MCV – 94.1; 93.2; 93.1 (82-98 fl); leucocytes– 11.9; 10.2; 9.33 (3.5 – 10.5 x 10<sup>9</sup>/l); platelets – 233; 265; 257 (140- 400 x 10<sup>9</sup>/l);

Biochemistry: glucose – 7.87 (2.8 – 6.1 mmol/l); blood sugar profile – 8.7; 7.9; 9.1; creatinine – 100 (74 – 134 μmol/l); urea – 13.5 (3.2 – 8.2 mmol/l); total protein – 64 (60 – 83 g/l); albumin – 40 (35 – 52 g/l); LDH – 372 (230 – 460 U/l); HBDH – 112 (90 – 197 U/l); potassium – 3.7 (3.5 – 5.6 mmol/l); sodium – 133 (136 – 151 mmol/l); chlorides – 95 (96 – 110 mmol/l); IgA – 1.39 (0.7 – 4.5 g/l); IgM – 0.36 (0.4 – 2.3 g/l); IgG – 5.56 (7 – 16 g/l); fibrinogen – 3.9 (2.0 – 4.5 g/l); prothrombin time - < 5; 93.7; 115.2; 112.5; 115.2 (70 – 120%); INR – 14.89; 0.98; 0.90;

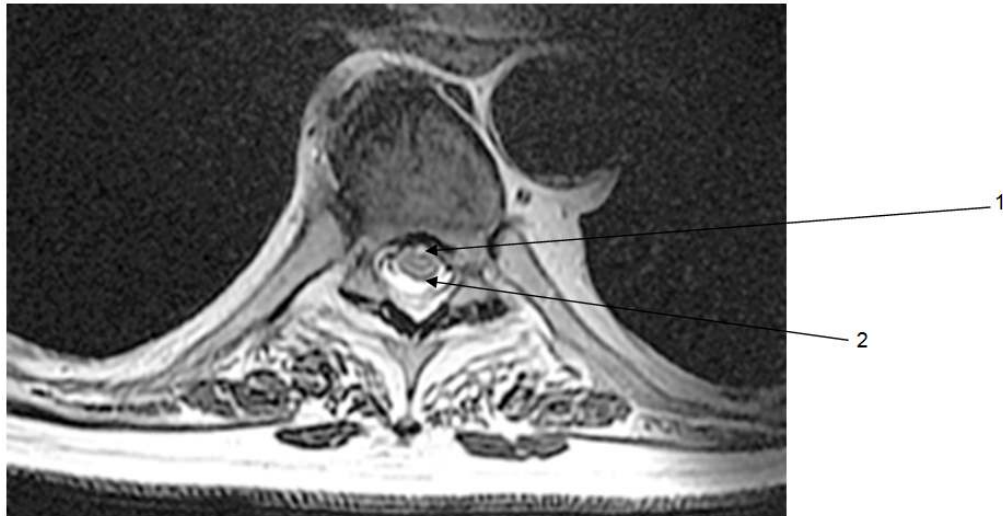
Cerebrospinal fluid investigation: before centrifuge - bloody, after centrifuge - xanthochromic; leucocytes – 11 (4 – 6 x 10<sup>6</sup>/l); erythrocytes – 3.072 (0 – 3 x 10<sup>9</sup>/l); protein – 1.181(0.15 – 0.45 g/l); glucose 4.5 (2.2 – 3.9 mmol/l); sodium – 146 (138 – 153 mmol/l); potassium – 2.9 (2.7 – 3.2 mmol/l); chlorides – 109 (115 – 132 mmol/l); IgA – 12.53 (0-3 mg/l); IgM – 2.03 (0-0.3 mg/l); Ig G – 82.49 (0-30 mg/l); sediment: polymorphonuclear cells – 24%; monocytes – 11%; lymphocytes – 65%; fibrin web – positive.

Neuroimaging: CT scan of the thoracic and lumbar spine - deforming spondylosis, no signs of traumatic, vertebrogenic or discogenic compression of the spinal cord.

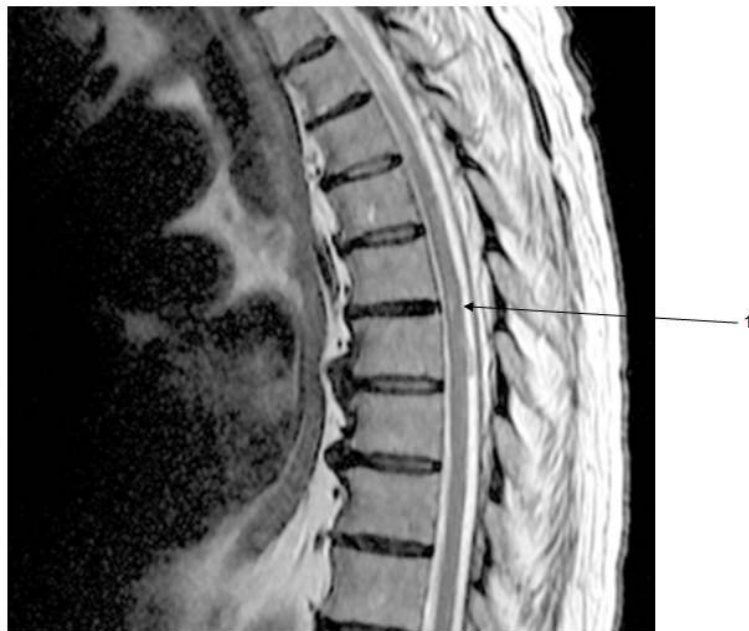Contrast MRI of the thoracic spine (Signa HDxt 1.5 T): Two pathological lesions were visualized. The first one is a hyperintense on T<sub>2</sub> and iso- to

hypoinense on T<sub>1</sub> intraspinal, 8 mm lesion in the craniocaudal plane, localized in the anterior funiculi of Th<sub>6-7</sub> segments. There is no local expansion of the lesion and perifocal edema. The second one is a lentiform 7 mm lesion with a relatively low intensity, localized in the posterior spinal arachnoid space in the right parasagittal part of Th<sub>7</sub> segment. There are areas with low to

lacking signal intensity in the second lesion on axial plane of T2 MERGE (a technique with high sensitivity to components with paramagnetic features – hemosiderin). In conclusion, the first lesion is associated with a spinal ischemic stroke (Figs. 1, 2), while the second lesion is associated with a small chronic subarachnoid hemorrhage (Fig. 1).



**Fig. 1. MRT T<sub>2</sub> transversal section (Th6 vertebra)**  
1- Ischemic lesion  
2 – Subarachnoid hemorrhage



**Fig. 2. MRT T<sub>2</sub> sagittal section**  
1- Ischemic lesion

The patient was treated with: electrolyte solutions (physiological saline solution) 1000 ml daily, vasoactive drugs (Pentoxiphylline) 800 mg daily, Fraxiparine 0.8 ml daily.

The patient did not complain about headache at the onset or during the clinical course. At the end of a 12-days hospital stay the patient was satisfactorily improved. The motor deficit improved to moderate left leg paresis and light right leg paresis, Babinski sign was bilaterally positive, there was areflexia for the deep tendon reflexes of low extremities. The distal hypesthesia was below Th<sub>10</sub> dermatome. There was no retention of urine and faeces. The recommended home treatment included Clopidogrel 75 mg daily and Pentoxiphylline 800 mg daily.

Four months later, following 3 intensive courses of physiotherapy, the patient had complaints only about slight left leg weakness. He was able to walk without help and resumed his daily activities. From the neurological examination there were only discrete residual pyramidal signs – inferior left latent monoparesis and positive Babinski sign bilaterally.

### 3. DISCUSSION

This case report is of interest not only because of the extreme rarity of sSAH, but also because of the unique combination with an ischemic lesion of the spinal cord. The pathogenetic association of the two lesions is speculative. Despite the lack of a consensus on specific neuroimaging findings of sSAH [4], the sSAH lesion in our case report corresponds to the description of a case with spontaneous sSAH associated with a subdural hematoma at different spinal levels [2]. The single case report of a 67-year old woman with spinal infarction associated with sSAH as a consequence of multiple dissecting aneurysms of spinal arteries is similar to our case report regarding complaints (sudden onset with severe back pain and discomfort in the lower extremities), clinical manifestations (paraparesis and sphincter disturbance), MRI findings (spinal infarction at the levels of T8 and T10, and sSAH), and outcome (uneventful clinical course and recovery) [6].

One hypothetic explanation of our case report pathogenesis is an asymptomatic sSAH with a subsequent spinal cord ischemia as a result of vasospasm, clinically manifested by a severe neurological deficit. The dorsal localization of

sSAH is usually associated with thecal sac compression, the ventral one, however, does not result in neurological symptoms [2]. In our case report the sSAH is in the dorsal spinal subarachnoid space, without causing thecal sac compression, and the patient is with a severe neurological deficit. This fact, again with the topic localization of both lesions, suggest ischemia, a result of vasospasm, as a cause of the neurological deficit, but not blood flow reduction because of compression of an extraspinal intradural blood collection. There is a case report in literature with lower motor neuron paraplegia as a result of a spinal stroke in a patient with an aneurysm of the anterior communicating artery and most probably related to vasospasm of spinal cord arteries [7]. The latter, as well as our case report, are examples for ischemic stroke of unusual cause. Actually ischemic stroke of unusual cause was observed only in 4.3% of all first-ever strokes and 6% of all first-ever ischemic strokes in a recent clinical study of ischemic stroke of unusual cause [8].

According to another hypothesis there could be no pathogenetic association of the two disorders. Therefore the sSAH is a chronic condition, most probably a consequence of a drug-induced state of hypocoagulability, while the ischemic spinal cord lesion is caused by thromboembolism. The patient's concomitant diseases (atrial fibrillation, diabetes mellitus, arterial hypertension, dyslipidemia, ischemic heart disease) and the anticoagulation therapy are risk factors for both thrombosis/thromboembolism and hemorrhage.

Etiology of sSAH (spontaneous or secondary) is another issue for discussion. At the time of admission the patient is in a state of hypocoagulability with a possible complication sSAH, but according to the MRI data, sSAH is chronic, so we could not be sure about the coagulability state at the time of sSAH initiation. Having in mind the duration of sSAH (days to weeks) and the half-life of Acenocumarol (8-11 hours) there is only theoretical possibility about an association of the hypocoagulability with sSAH initiation. Spontaneous sSAH with subsequent hypocoagulability state as a result of poor compliance cannot be excluded as well. To some extent the latter corresponds to the small amount of blood in the posterior spinal space. Theoretically a spontaneous sSAH caused by a state of hypocoagulability would be hardly self limiting, but would result in a hematoma, which is a rare complication [2,9]. MRI angiography will be useful in clarifying the presence of

factors explaining sSAH (AVM, aneurysm, vasculitis).

#### 4. CONCLUSION

Our case report raises the question about the pathogenetic mechanisms of late ischemic complications in patients with sSAH. The domination of symptoms of these late complications and the subclinical manifestations of the main disease - sSAH makes the diagnosis a difficult one. Therefore MRI angiography is needed in every patient with acute or subacute syndrome of spinal cord lesion, in case a spinal cord compression is excluded. Spinal SAH etiology clarification is also important for an adequate and timely therapeutic approach (drug therapy or surgical treatment) and outcome.

#### CONSENT

All authors declare that 'written informed consent was obtained from the patient for publication of this paper and accompanying images.

#### ETHICAL APPROVAL

All authors hereby declare that all experiments have been examined and approved by the appropriate ethics committee and have therefore been performed in accordance with the ethical standards laid down in the 1964 declaration of Helsinki.

#### COMPETING INTERESTS

Authors have declared that no competing interests exist.

#### REFERENCES

1. VanGijn J, Kerr RS, Rinkel GJ. Subarachnoid haemorrhage. *Lancet*. 2007; 369:306-318.
2. Kakitsubata Y, Savroula J, Theodorou, Theorodou D, Miyata Y, Ito Y, Yuki Y, Honbu K, Maehara T. Spontaneous spinal subarachnoid hemorrhage associated with subdural hematoma at different spinal levels. Case report. *Emerg Radiol*. 2010;17:69-72.
3. Domenicucci M, Ramieri A, Paolini S, Russo N, Occhiogrosso G, Di Biasi C, Delfini R. Spinal subarachnoid hematomas: Our experience and literature review. *Acta Neurochir (Wien)*. 2005; 147(7):741-750.
4. Sasaji T, Shinagawa K, Matsuya S. Spontaneous thoracic spinal subarachnoid hemorrhage diagnosed with brain computed tomography. *Tohoku J Exp Med*. 2013;231:139-144.
5. Russell NA, Benoit BG. Spinal subdural hematoma. A review. *Surg Neurol*. 1983;20(2):133-137.
6. Sato K, Roccatagliata L, Depuydt S, Rodeschi G. Multiple aneurysms of thoracic spinal cord arteries presenting with spinal infarction and subarachnoid hemorrhage: Case report and literature review. *Neurosurgery*. 2012;71(5):E1053-1058.
7. Krishna V, Lazaridis C, Ellegala D, Glazier S, Kindy M, Spampinato M, Chalela J. Spinal cord infarction associated with subarachnoid hemorrhage. *Clin Neurol Neurosurg*. 2012;114(7):1030-1032.
8. Arboix A, Bechich S, Oliveres M, Garcia-Eroles L, Massons J, Targa C. Ischemic stroke of unusual cause: Clinical features, etiology and outcome. *Eur J of Neurol*. 2001;8:133-139.
9. Rowland MJ, Hadjipavlou G, Kelly M, Westbrook J, Pattinson K. Delayed cerebral ischaemia after subarachnoid haemorrhage: Looking beyond vasospasm. *Br J Anaesth*. 2012;109(3):315-329.

© 2016 Viteva and Chaneva; This is an Open Access article distributed under the terms of the Creative Commons Attribution License (<http://creativecommons.org/licenses/by/4.0>), which permits unrestricted use, distribution, and reproduction in any medium, provided the original work is properly cited.

*Peer-review history:*  
*The peer review history for this paper can be accessed here:*  
<http://sciencedomain.org/review-history/14205>